

McKinley | O'Loughlin | Pennefather-O'Brien

# Human Anatomy

Sixth Edition



Mc  
Graw  
Hill

sixth edition

# Human Anatomy

**Michael P. McKinley**

Glendale Community College (Emeritus)


**Valerie Dean O'Loughlin**

Indiana University

**Elizabeth E. Pennefather-O'Brien**

Medicine Hat College

**Mc  
Graw  
Hill**



## HUMAN ANATOMY, SIXTH EDITION

Published by McGraw-Hill Education, 2 Penn Plaza, New York, NY 10121. Copyright ©2021 by McGraw-Hill Education. All rights reserved. Printed in the United States of America. Previous editions ©2017, 2015, and 2012. No part of this publication may be reproduced or distributed in any form or by any means, or stored in a database or retrieval system, without the prior written consent of McGraw-Hill Education, including, but not limited to, in any network or other electronic storage or transmission, or broadcast for distance learning.

Some ancillaries, including electronic and print components, may not be available to customers outside the United States.

This book is printed on acid-free paper.

1 2 3 4 5 6 7 8 9 LWI 24 23 22 21 20

ISBN 978-1-260-25135-7 (bound edition)  
MHID 1-260-25135-7 (bound edition)  
ISBN 978-1-260-44382-0 (loose-leaf edition)  
MHID 1-260-44382-5 (loose-leaf edition)

Portfolio Manager: *Matthew Garcia*  
Product Developer: *Donna Nemmers*  
Marketing Manager: *Valerie Kramer*  
Content Project Managers: *Jessica Portz, Brent dela Cruz, Sandra Schnee*  
Buyer: *Sandy Ludovissy*  
Design: *Jessica Cuevas/Deborah Kubiak*  
Content Licensing Specialist: *Lori Hancock*  
Cover Image: ©*Tatiana Kolesnikova/Getty Images*  
Compositor: *MPS Limited*

All credits appearing on page or at the end of the book are considered to be an extension of the copyright page.


### Library of Congress Cataloging-in-Publication Data

McKinley, Michael P., author. | O'Loughlin, Valerie Dean, author. |  
Pennefather-O'Brien, Elizabeth, author.  
Human anatomy / Michael P. McKinley, Glendale Community College  
(Emeritus), Valerie Dean O'Loughlin, Indiana University, Elizabeth E.  
Pennefather-O'Brien, Medicine Hat College.  
Sixth edition. | New York, NY : MHE, [2021] | Includes index.  
LCCN 2019017443 | ISBN 9781260251357 (student edition : alk. paper)  
LCSH: Human anatomy.  
LCC QM23.2 .M38 2021 | DDC 612—dc23  
LC record available at <https://lcn.loc.gov/2019017443>


The Internet addresses listed in the text were accurate at the time of publication. The inclusion of a website does not indicate an endorsement by the authors or McGraw-Hill Education, and McGraw-Hill Education does not guarantee the accuracy of the information presented at these sites.

[mheducation.com/highered](http://mheducation.com/highered)





# About the Authors



Courtesy of Janyce McKinley

**MICHAEL P. MCKINLEY** received his undergraduate degree from the University of California, and both MS and PhD degrees from Arizona State University. In 1978, he accepted a postdoctoral fellowship at the University of California at San Francisco (UCSF) Medical School in the laboratory of Dr. Stanley Prusiner, where he worked for 12 years investigating prions and prion-diseases. In 1980, he became a member of the anatomy faculty at the UCSF Medical School, where he taught medical histology for 10 years while continuing to do research on prions. During this time, he was an author or co-author of more than 80 scientific papers.

Michael was a member of the biology faculty at Glendale Community College from 1991 to 2012, where he taught undergraduate anatomy and physiology, general biology, and genetics. Between 1991 and 2000, he also participated in Alzheimer disease research and served as director of the Brain Donation Program at the Sun Health Research Institute, as well as teaching developmental biology and human genetics at Arizona State University, West. His vast experience in histology, neuroanatomy, and cell biology greatly shaped the related content in *Human Anatomy*. He retired from active teaching in 2012 and continues to be an active member of the Human Anatomy and Physiology Society (HAPS). Michael is coauthor of the McKinley/O’Loughlin/Bidle: *Anatomy & Physiology: An Integrative Approach*, Third Edition, textbook. He resides in Tempe, AZ, with his wife Jan.




Courtesy of Indiana University

**VALERIE DEAN O’LOUGHLIN** received her undergraduate degree from the College of William and Mary, and her PhD in biological anthropology from Indiana University. She is Professor of Anatomy at Indiana University School of Medicine–Bloomington, where she teaches human gross anatomy to medical students, basic human anatomy to undergraduates, and human anatomy for medical imaging evaluation to undergraduate and graduate students. She also teaches a graduate pedagogical methods course and mentors PhD students pursuing anatomy education research. She is a fellow of the American Association of Anatomists (AAA), a President Emeritus of the Human Anatomy and Physiology Society (HAPS), and a current member of the HAPS Steering Committee. She received the AAA Basmajian Award for excellence in teaching gross anatomy and outstanding accomplishments in scholarship in education, and in 2018 she was awarded the AAA Henry Gray Distinguished Educator Award. In 2014 she received the Scholar Educator award from the Indiana University School of Medicine, which recognizes a single faculty member who approaches teaching through a scholarly lens. Valerie is coauthor of the McKinley/O’Loughlin/Bidle: *Anatomy & Physiology: An Integrative Approach*, Third Edition, textbook.



Courtesy of Medicine Hat College

**ELIZABETH E. PENNEFATHER-O’BRIEN** received her undergraduate degree from the University of Alberta, Edmonton, Alberta, Canada, and her MA and PhD degrees in biological anthropology from Indiana University, Bloomington. She is the Dean of Science and Health at Medicine Hat College in Alberta, where she taught anatomy and physiology to nursing and paramedic students for 14 years. She has also taught physiology and biology for nonmajors. Elizabeth is active in several professional organizations, including sitting on the board of the Human Anatomy and Physiology Society (HAPS). In 2012, Elizabeth was one of five inaugural recipients of the College Sector Educator Awards bestowed by the Society of Teaching and Learning in Higher Education (STLHE). She is recognized as a 3M Teaching Fellow.



# Brief Contents

|           |  |     |
|-----------|--|-----|
| Chapter 1 | A First Look at Anatomy                        | 1   |
| Chapter 2 | The Cell: Basic Unit of Structure and Function | 23  |
| Chapter 3 | Embryology                                     | 54  |
| Chapter 4 | Tissue Level of Organization                   | 80  |
| Chapter 5 | Integumentary System                           | 117 |

## S K E L E T A L   S Y S T E M

|           |                       |     |
|-----------|-----------------------|-----|
| Chapter 6 | Cartilage and Bone    | 144 |
| Chapter 7 | Axial Skeleton        | 170 |
| Chapter 8 | Appendicular Skeleton | 216 |
| Chapter 9 | Articulations         | 248 |

## M U S C U L A R   S Y S T E M

|            |                                |     |
|------------|--------------------------------|-----|
| Chapter 10 | Muscle Tissue and Organization | 283 |
| Chapter 11 | Axial Muscles                  | 316 |
| Chapter 12 | Appendicular Muscles           | 347 |

|            |                 |     |
|------------|-----------------|-----|
| Chapter 13 | Surface Anatomy | 390 |
|------------|-----------------|-----|

## N E R V O U S   S Y S T E M

|            |                                    |     |
|------------|------------------------------------|-----|
| Chapter 14 | Nervous Tissue                     | 407 |
| Chapter 15 | Brain and Cranial Nerves           | 431 |
| Chapter 16 | Spinal Cord and Spinal Nerves      | 477 |
| Chapter 17 | Pathways and Integrative Functions | 508 |
| Chapter 18 | Autonomic Nervous System           | 530 |
| Chapter 19 | Senses: General and Special        | 552 |

|            |                  |     |
|------------|------------------|-----|
| Chapter 20 | Endocrine System | 595 |
|------------|------------------|-----|

## C A R D I O V A S C U L A R   S Y S T E M

|            |                         |     |
|------------|-------------------------|-----|
| Chapter 21 | Blood                   | 625 |
| Chapter 22 | Heart                   | 645 |
| Chapter 23 | Vessels and Circulation | 673 |

|            |                     |     |
|------------|---------------------|-----|
| Chapter 24 | Lymphatic System    | 714 |
| Chapter 25 | Respiratory System  | 737 |
| Chapter 26 | Digestive System    | 769 |
| Chapter 27 | Urinary System      | 806 |
| Chapter 28 | Reproductive System | 830 |

Preface xii

## Chapter 1

### A First Look at Anatomy 1

- 1.1 History of Human Anatomy 2
- 1.2 Definition of Anatomy 3
  - 1.2a Microscopic Anatomy 3
  - 1.2b Gross Anatomy 4
- 1.3 Structural Organization of the Body 5
  - 1.3a Characteristics of Living Things 6
  - 1.3b Introduction to Organ Systems 6
- 1.4 Precise Language of Anatomy 11
  - 1.4a Anatomic Position 11
  - 1.4b Sections and Planes 11
  - 1.4c Anatomic Directions 12
  - 1.4d Regional Anatomy 13
  - 1.4e Body Cavities and Membranes 14
  - 1.4f Abdominopelvic Regions and Quadrants 16

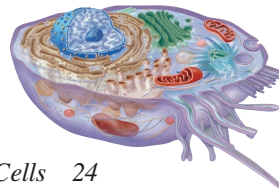


- 3.3 Pre-embryonic Period 60
  - 3.3a Fertilization 60
  - 3.3b Cleavage 63
  - 3.3c Implantation 64
  - 3.3d Formation of the Bilaminar Germinal Disc and the Extraembryonic Membranes 64
  - 3.3e Development of the Placenta 65
- 3.4 Embryonic Period 67
  - 3.4a Gastrulation 68
  - 3.4b Folding of the Embryonic Disc 68
  - 3.4c Differentiation of Ectoderm 70
  - 3.4d Differentiation of Mesoderm 70
  - 3.4e Differentiation of Endoderm 71
  - 3.4f Organogenesis 74
- 3.5 Fetal Period 74

## Chapter 2

### The Cell: Basic Unit of Structure and Function 23

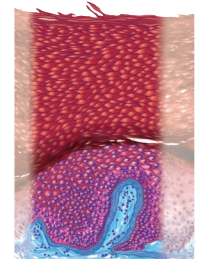
- 2.1 The Study of Cells 24
  - 2.1a Using the Microscope to Study Cells 24
  - 2.1b General Functions of Human Body Cells 25
- 2.2 A Prototypical Cell 27
- 2.3 Plasma Membrane 30
  - 2.3a Composition and Structure of Membranes 30
  - 2.3b Protein-Specific Functions of the Plasma Membrane 31
  - 2.3c Transport Across the Plasma Membrane 32
- 2.4 Cytoplasm 37
  - 2.4a Cytosol 37
  - 2.4b Inclusions 37
  - 2.4c Organelles 37
- 2.5 Nucleus 44
  - 2.5a Nuclear Envelope 44
  - 2.5b Nucleoli 44
  - 2.5c DNA, Chromatin, and Chromosomes 45
- 2.6 Life Cycle of the Cell 46
  - 2.6a Interphase 46
  - 2.6b Mitotic (M) Phase 47
- 2.7 Aging and the Cell 49



## Chapter 4

### Tissue Level of Organization 80

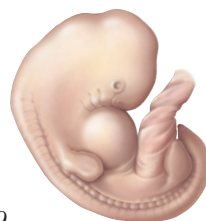- 4.1 Epithelial Tissue 81
  - 4.1a Characteristics of Epithelial Tissue 81
  - 4.1b Functions of Epithelial Tissue 82
  - 4.1c Specialized Structures of Epithelial Tissue 82
  - 4.1d Classification of Epithelial Tissue 83
  - 4.1e Types of Epithelium 84
  - 4.1f Glands 91
- 4.2 Connective Tissue 95
  - 4.2a Characteristics of Connective Tissue 95
  - 4.2b Functions of Connective Tissue 96
  - 4.2c Development of Connective Tissue 96
  - 4.2d Classification of Connective Tissue 96
- 4.3 Body Membranes 108
- 4.4 Muscle Tissue 109
  - 4.4a Classification of Muscle Tissue 109
- 4.5 Nervous Tissue 111
  - 4.5a Characteristics of Neurons 111
- 4.6 Tissue Change and Aging 112
  - 4.6a Tissue Change 112
  - 4.6b Tissue Aging 112



## Chapter 3

### Embryology 54

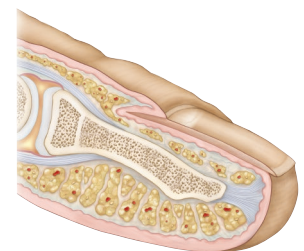- 3.1 Overview of Embryology 55
- 3.2 Gametogenesis 56
  - 3.2a Meiosis 57
  - 3.2b Oocyte Development (Oogenesis) 59
  - 3.2c Sperm Development (Spermatogenesis) 60




## Chapter 5

### Integumentary System 117

- 5.1 Structure and Functions of the Integument 118
  - 5.1a Integument Structure 118
  - 5.1b Integument Functions 119
- 5.2 Epidermis 120
  - 5.2a Epidermal Strata 120
  - 5.2b Variations in the Epidermis 122



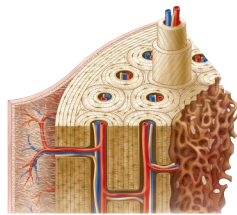


- 5.3 Dermis 124
  - 5.3a Papillary Layer of the Dermis 124
  - 5.3b Reticular Layer of the Dermis 125
  - 5.3c Lines of Cleavage and Stretch Marks 125
  - 5.3d Innervation and Blood Supply 125
- 5.4 Subcutaneous Layer 126
- 5.5 Integumentary Structures Derived from Epidermis 127
  - 5.5a Nails 128
  - 5.5b Hair 128
  - 5.5c Exocrine Glands of the Skin 131
- 5.6 Integument Repair and Regeneration 135
- 5.7 Aging of the Integument 136
  - 5.7a Skin Cancer 137
- 5.8 Development of the Integumentary System 138
  - 5.8a Integument Development 138
  - 5.8b Nail Development 139
  - 5.8c Hair Development 139
  - 5.8d Sebaceous and Sweat Gland Development 139
  - 5.8e Mammary Gland Development 139

## Chapter 6

### Cartilage and Bone 144

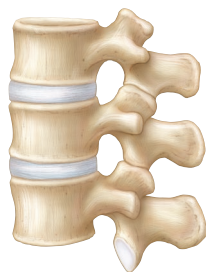
- 6.1 Cartilage 145
  - 6.1a Functions of Cartilage 145
  - 6.1b Growth Patterns of Cartilage 146
- 6.2 Bone 146
  - 6.2a Functions of Bone 146
- 6.3 Classification and Anatomy of Bones 148
  - 6.3a General Structure and Gross Anatomy of Long Bones 148
- 6.4 Ossification 154
  - 6.4a Intramembranous Ossification 154
  - 6.4b Endochondral Ossification 156
  - 6.4c Epiphyseal Plate Morphology 157
  - 6.4d Growth of Bone 158
  - 6.4e Blood Supply and Innervation 160
- 6.5 Maintaining Homeostasis and Promoting Bone Growth 161
  - 6.5a Effects of Hormones 161
  - 6.5b Effects of Vitamins 161
  - 6.5c Effects of Exercise 161
  - 6.5d Fracture and Repair 163
- 6.6 Bone Markings 164
- 6.7 Aging of the Skeletal System 165



## Chapter 7

### Axial Skeleton 170

- 7.1 Skull 172
  - 7.1a Views of the Skull and Landmark Features 173
  - 7.1b Sutures 182
  - 7.1c Bones of the Cranium 182
  - 7.1d Bones of the Face 190
  - 7.1e Nasal Complex 195
  - 7.1f Paranasal Sinuses 195



- 7.1g Orbital Complex 195
- 7.1h Bones Associated with the Skull 195
- 7.2 Sexually Dimorphic Features of the Skull 198
- 7.3 Aging of the Skull 198
- 7.4 Vertebral Column 201
  - 7.4a Divisions of the Vertebral Column 201
  - 7.4b Spinal Curvatures 201
  - 7.4c Vertebral Anatomy 202
- 7.5 Thoracic Cage 209
  - 7.5a Sternum 209
  - 7.5b Ribs 209
- 7.6 Aging of the Axial Skeleton 211
- 7.7 Development of the Axial Skeleton 211

## Chapter 8

### Appendicular Skeleton 216

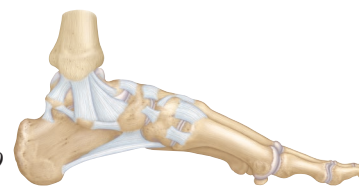
- 8.1 Pectoral Girdle 217
  - 8.1a Clavicle 217
  - 8.1b Scapula 217
- 8.2 Upper Limb 221
  - 8.2a Humerus 221
  - 8.2b Radius and Ulna 221
  - 8.2c Carpals, Metacarpals, and Phalanges 226
- 8.3 Pelvic Girdle 226
  - 8.3a Os Coxae 228
  - 8.3b True and False Pelves 229
  - 8.3c Sexually Dimorphic Features of the Pelves 229
- 8.4 Lower Limb 232
  - 8.4a Femur 232
  - 8.4b Patella 236
  - 8.4c Tibia and Fibula 236
  - 8.4d Tarsals, Metatarsals, and Phalanges 237
- 8.5 Aging of the Appendicular Skeleton 241
- 8.6 Development of the Appendicular Skeleton 241



## Chapter 9

### Articulations 248

- 9.1 Articulations (Joints) 249
  - 9.1a Classification of Joints 249
- 9.2 Fibrous Joints 250
  - 9.2a Gomphoses 250
  - 9.2b Sutures 251
  - 9.2c Syndesmoses 251
- 9.3 Cartilaginous Joints 251
  - 9.3a Synchondroses 251
  - 9.3b Symphyses 252
- 9.4 Synovial Joints 252
  - 9.4a General Anatomy of Synovial Joints 253
  - 9.4b Classifications of Synovial Joints 254
  - 9.4c Movements at Synovial Joints 256
- 9.5 Selected Articulations in Depth 261
  - 9.5a Joints of the Axial Skeleton 261
  - 9.5b Joints of the Pectoral Girdle and Upper Limbs 264
  - 9.5c Joints of the Pelvic Girdle and Lower Limbs 270

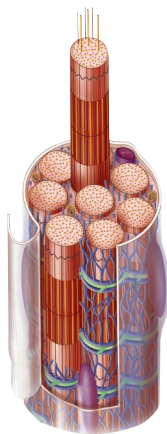


- 9.6 Aging of the Joints 277
- 9.7 Development of the Joints 279

## Chapter 10

### Muscle Tissue and Organization 283

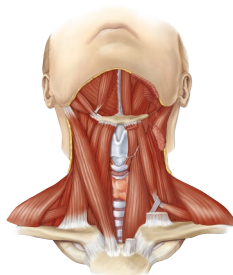
- 10.1 Properties of Muscle Tissue 284
- 10.2 Characteristics of Skeletal Muscle Tissue 284
  - 10.2a Functions of Skeletal Muscle Tissue 284
  - 10.2b Gross Anatomy of Skeletal Muscle 284
  - 10.2c Microscopic Anatomy of Skeletal Muscle 287
- 10.3 Contraction of Skeletal Muscle Fibers 293
  - 10.3a The Sliding Filament Theory 293
  - 10.3b Neuromuscular Junctions 293
  - 10.3c Physiology of Muscle Contraction 294
  - 10.3d Muscle Contraction: A Summary 296
  - 10.3e Motor Units 298
- 10.4 Types of Skeletal Muscle Fibers 299
  - 10.4a Distribution of Slow Oxidative, Fast Oxidative, and Fast Glycolytic Fibers 300
- 10.5 Skeletal Muscle Fiber Organization 301
  - 10.5a Circular Muscles 301
  - 10.5b Parallel Muscles 301
  - 10.5c Convergent Muscles 301
  - 10.5d Pennate Muscles 302
- 10.6 Exercise and Skeletal Muscle 302
  - 10.6a Muscle Hypertrophy 303
  - 10.6b Muscle Atrophy 303
- 10.7 Levers and Joint Biomechanics 303
  - 10.7a Classes of Levers 303
  - 10.7b Actions of Skeletal Muscles 303
- 10.8 The Naming of Skeletal Muscles 305
- 10.9 Characteristics of Cardiac and Smooth Muscle 306
  - 10.9a Cardiac Muscle 306
  - 10.9b Smooth Muscle 307
- 10.10 Aging and the Muscular System 307
- 10.11 Development of the Muscular System 307



## Chapter 11

### Axial Muscles 316

- 11.1 Muscles of the Head and Neck 317
  - 11.1a Muscles of Facial Expression 317
  - 11.1b Extrinsic Eye Muscles 322
  - 11.1c Muscles of Mastication 326
  - 11.1d Muscles That Move the Tongue 326
  - 11.1e Muscles of the Pharynx 327
  - 11.1f Muscles of the Anterior Neck 328
  - 11.1g Muscles That Move the Head and Neck 331

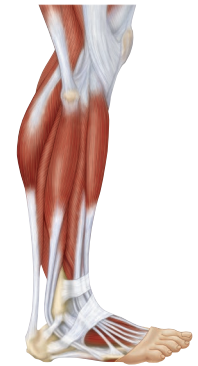

- 11.2 Muscles of the Vertebral Column 334
- 11.3 Muscles of Respiration 336
- 11.4 Muscles of the Abdominal Wall 339
- 11.5 Muscles of the Pelvic Floor 342

## Chapter 12

### Appendicular Muscles 347

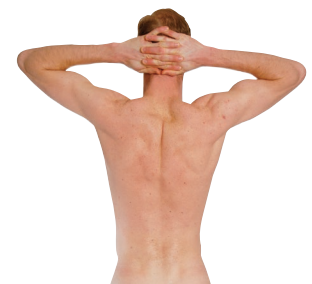- 12.1 Muscles of the Pectoral Girdle and Upper Limb 348
  - 12.1a Muscles That Move the Pectoral Girdle 348
  - 12.1b Muscles That Move the Glenohumeral Joint/Arm 353
  - 12.1c Arm and Forearm Muscles That Move the Elbow Joint/Forearm 356
  - 12.1d Forearm Muscles That Move the Wrist Joint, Hand, and Fingers 360
  - 12.1e Intrinsic Muscles of the Hand 367
- 12.2 Muscles of the Pelvic Girdle and Lower Limb 369
  - 12.2a Muscles That Move the Hip Joint/Thigh 369
  - 12.2b Thigh Muscles That Move the Knee Joint/Leg 374
  - 12.2c Leg Muscles 377
  - 12.2d Intrinsic Muscles of the Foot 383



## Chapter 13

### Surface Anatomy 390

- 13.1 A Regional Approach to Surface Anatomy 391
- 13.2 Head Region 391
  - 13.2a Cranium 392
  - 13.2b Face 392
- 13.3 Neck Region 393
- 13.4 Trunk Region 395
  - 13.4a Thorax 395
  - 13.4b Abdominopelvic Region 395
  - 13.4c Back 397
- 13.5 Shoulder and Upper Limb Region 398
  - 13.5a Shoulder 398
  - 13.5b Axilla 398
  - 13.5c Arm 398
  - 13.5d Forearm 399
  - 13.5e Hand 399
- 13.6 Lower Limb Region 401
  - 13.6a Gluteal Region 401
  - 13.6b Thigh 401
  - 13.6c Leg 402
  - 13.6d Foot 404

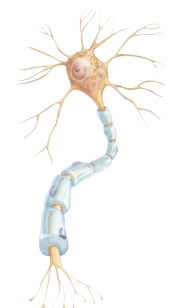


©McGraw-Hill Education/Jw Ramsey, photographer


## Chapter 14

### Nervous Tissue 407

- 14.1 Organization of the Nervous System 408
  - 14.1a Structural Organization: Central and Peripheral Nervous Systems 408
  - 14.1b Functional Organization: Sensory and Motor Nervous Systems 408





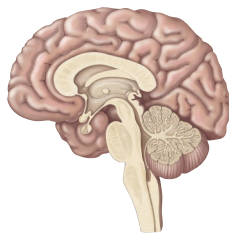


- 14.2 Cytology of Nervous Tissue 410
  - 14.2a Neurons 410
  - 14.2b Glial Cells 413
- 14.3 Myelination of Axons 417
  - 14.3a Myelination 417
  - 14.3b Nerve Impulse Conduction 418
- 14.4 Axon Regeneration 420
- 14.5 Nerves 420
- 14.6 Synapses 422
  - 14.6a Synaptic Communication 423
- 14.7 Neural Integration and Neural Circuits 425
- 14.8 Development of the Nervous System 426

## Chapter 15

### Brain and Cranial Nerves 431

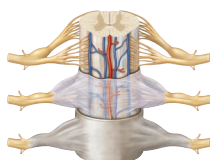
- 15.1 Brain Development and Tissue Organization 432
  - 15.1a Embryonic Development of the Brain 433
  - 15.1b Organization of Neural Tissue Areas in the Brain 436
- 15.2 Support and Protection of the Brain 438
  - 15.2a Cranial Meninges 440
  - 15.2b Brain Ventricles 442
  - 15.2c Cerebrospinal Fluid 442
  - 15.2d Blood-Brain Barrier 444
- 15.3 Cerebrum 446
  - 15.3a Cerebral Hemispheres 446
  - 15.3b Functional Areas of the Cerebrum 448
  - 15.3c Central White Matter 451
  - 15.3d Cerebral Nuclei 453
- 15.4 Diencephalon 454
  - 15.4a Epithalamus 455
  - 15.4b Thalamus 455
  - 15.4c Hypothalamus 456
- 15.5 Brainstem 457
  - 15.5a Midbrain 457
  - 15.5b Pons 459
  - 15.5c Medulla Oblongata 460
- 15.6 Cerebellum 461
  - 15.6a Cerebellar Peduncles 462
- 15.7 Limbic System 462
- 15.8 Cranial Nerves 465



## Chapter 16

### Spinal Cord and Spinal Nerves 477

- 16.1 Gross Anatomy of the Spinal Cord 478
- 16.2 Spinal Cord Meninges 480
- 16.3 Sectional Anatomy of the Spinal Cord 482
  - 16.3a Distribution of Gray Matter 482
  - 16.3b Distribution of White Matter 483
- 16.4 Spinal Nerves 484
  - 16.4a Spinal Nerve Distribution 484
  - 16.4b Nerve Plexuses 486

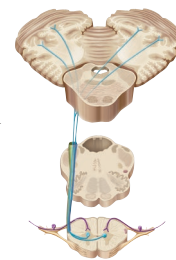


- 16.4c Intercostal Nerves 487
- 16.4d Cervical Plexuses 487
- 16.4e Brachial Plexuses 488
- 16.4f Lumbar Plexuses 493
- 16.4g Sacral Plexuses 496
- 16.5 Reflexes 497
  - 16.5a Components of a Reflex Arc 500
  - 16.5b Examples of Spinal Reflexes 502
  - 16.5c Reflex Testing in a Clinical Setting 502
- 16.6 Development of the Spinal Cord 503

## Chapter 17

### Pathways and Integrative Functions 508

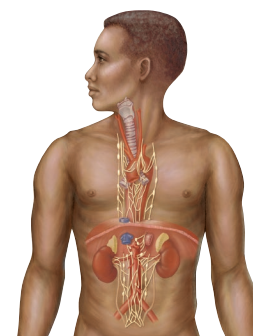
- 17.1 General Characteristics of Nervous System Pathways 509
- 17.2 Sensory Pathways 509
  - 17.2a Functional Anatomy of Sensory Pathways 510
- 17.3 Motor Pathways 513
  - 17.3a Functional Anatomy of Motor Pathways 513
  - 17.3b Levels of Processing and Motor Control 518
- 17.4 Higher-Order Processing and Integrative Functions 518
  - 17.4a Development and Maturation of Higher-Order Processing 519
  - 17.4b Hemispheric Lateralization 519
  - 17.4c Language 519
  - 17.4d Cognition 520
  - 17.4e Memory 521
  - 17.4f Consciousness 522
  - 17.4g Electroencephalogram 523
  - 17.4h Sleep 524
- 17.5 Aging and the Nervous System 525



## Chapter 18

### Autonomic Nervous System 530

- 18.1 Comparison of the Somatic and Autonomic Nervous Systems 531
  - 18.1a Motor Neurons of the Somatic Versus Autonomic Nervous System 532
- 18.2 Divisions of the Autonomic Nervous System 533
  - 18.2a Functional Differences 533
  - 18.2b Anatomic Differences in Lower Motor Neurons 534
- 18.3 Parasympathetic Division 535
  - 18.3a Cranial Components 535
  - 18.3b Pelvic Splanchnic Nerves 537
  - 18.3c Effects and General Functions of the Parasympathetic Division 537
- 18.4 Sympathetic Division 537
  - 18.4a Organization and Anatomy of the Sympathetic Division 537



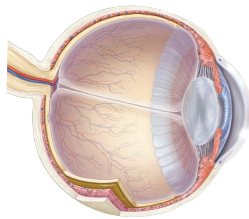


- 18.4b Sympathetic Pathways 540
- 18.4c Effects and General Functions of the Sympathetic Division 540
- 18.5 Other Features of the Autonomic Nervous System 542
  - 18.5a Autonomic Plexuses 542
  - 18.5b Enteric Nervous System 543
  - 18.5c Overview of ANS Neurotransmitters 544
  - 18.5d Autonomic Tone 545
  - 18.5e Dual Innervation 545
  - 18.5f Systems Controlled Only by the Sympathetic Division 546
  - 18.5g Autonomic Reflexes 546
- 18.6 CNS Control of Autonomic Function 548
- 18.7 Development of the Autonomic Nervous System 548

## Chapter 19

### Senses: General and Special 552

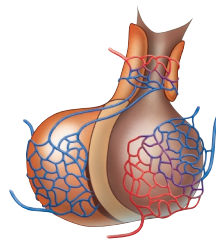
- 19.1 Introduction to Sensory Receptors 553
  - 19.1a Properties of Sensory Receptors 553
  - 19.1b Classification of Sensory Receptors 554
- 19.2 Tactile Receptors 557
  - 19.2a Unencapsulated Tactile Receptors 557
  - 19.2b Encapsulated Tactile Receptors 559
- 19.3 Olfaction 559
  - 19.3a Olfactory Receptor Cells 559
  - 19.3b Olfactory Discrimination 560
  - 19.3c Olfactory Pathways 560
- 19.4 Gustation 561
  - 19.4a Papillae and Taste Buds of the Tongue 561
  - 19.4b Gustatory Discrimination 562
  - 19.4c Gustatory Pathways 562
- 19.5 Vision 562
  - 19.5a Accessory Structures of the Eye 563
  - 19.5b Eye Structure 564
  - 19.5c Visual Pathways 572
  - 19.5d Development of the Eye 573
- 19.6 Equilibrium and Hearing 576
  - 19.6a External Ear 576
  - 19.6b Middle Ear 577
  - 19.6c Inner Ear 578
  - 19.6d Development of the Ear 589



## Chapter 20

### Endocrine System 595

- 20.1 Endocrine Glands and Hormones 596
  - 20.1a Overview of Hormones 596
  - 20.1b Negative and Positive Feedback 598
- 20.2 Hypothalamic Control of the Endocrine System 598
- 20.3 Pituitary Gland 601
  - 20.3a Anterior Pituitary 601
  - 20.3b Posterior Pituitary 604

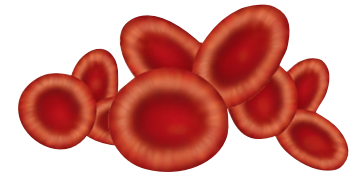


- 20.4 Thyroid Gland 605
  - 20.4a Synthesis of Thyroid Hormone by Thyroid Follicles 605
  - 20.4b Thyroid Gland–Pituitary Gland Negative Feedback 607
  - 20.4c Parafollicular Cells 608
- 20.5 Parathyroid Glands 610
- 20.6 Adrenal Glands 611
  - 20.6a Adrenal Cortex 611
  - 20.6b Adrenal Medulla 613
- 20.7 Pancreas 615
- 20.8 Pineal Gland and Thymus 618
- 20.9 Endocrine Functions of the Kidneys, Heart, Gastrointestinal Tract, and Gonads 618
  - 20.9a Kidneys 618
  - 20.9b Heart 619
  - 20.9c Gastrointestinal Tract 619
  - 20.9d Gonads 619
- 20.10 Aging and the Endocrine System 619
- 20.11 Development of the Endocrine System 619
  - 20.11a Adrenal Glands 619
  - 20.11b Pituitary Gland 619
  - 20.11c Thyroid Gland 621

## Chapter 21

### Blood 625

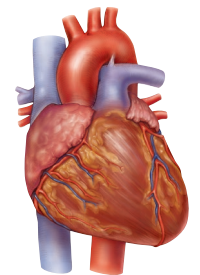
- 21.1 General Composition and Functions of Blood 626
  - 21.1a Components of Blood 626
  - 21.1b Functions of Blood 627
- 21.2 Blood Plasma 627
  - 21.2a Plasma Proteins 627
  - 21.2b Other Solutes in Plasma 627
  - 21.2c Differences Between Plasma and Interstitial Fluid 628
- 21.3 Formed Elements in the Blood 628
  - 21.3a Erythrocytes 629
  - 21.3b Leukocytes 636
  - 21.3c Platelets 638
- 21.4 Hematopoiesis: Production of Formed Elements 639
  - 21.4a Erythropoiesis 640
  - 21.4b Thrombopoiesis 642
  - 21.4c Leukopoiesis 642




## Chapter 22

### Heart 645

- 22.1 Overview of the Cardiovascular System 646
  - 22.1a Pulmonary and Systemic Circulations 646
  - 22.1b Position of the Heart 647
  - 22.1c Characteristics of the Pericardium 647
- 22.2 Anatomy of the Heart 648
  - 22.2a Heart Wall Structure 649
  - 22.2b External Heart Anatomy 649
  - 22.2c Internal Heart Anatomy: Chambers and Valves 649



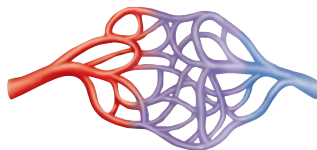


- 22.3 Coronary Circulation 656
- 22.4 How the Heart Beats: Electrical Properties of Cardiac Tissue 658
  - 22.4a Characteristics of Cardiac Muscle Tissue 658
  - 22.4b Contraction of Heart Muscle 658
  - 22.4c The Heart's Conducting System 658
- 22.5 Innervation of the Heart 661
- 22.6 Tying It All Together: The Cardiac Cycle 663
  - 22.6a Steps in the Cardiac Cycle 663
  - 22.6b Summary of Blood Flow During the Cardiac Cycle 663
- 22.7 Aging and the Heart 666
- 22.8 Development of the Heart 667

## Chapter 23

### Vessels and Circulation 673

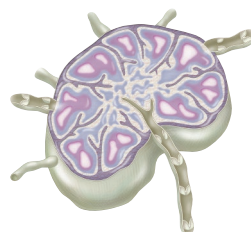
- 23.1 Anatomy of Blood Vessels 674
  - 23.1a Blood Vessel Tunics 674
  - 23.1b Arteries 674
  - 23.1c Capillaries 676
  - 23.1d Veins 678
- 23.2 Blood Pressure 681
- 23.3 Systemic Circulation 683
  - 23.3a General Arterial Flow Out of the Heart 683
  - 23.3b General Venous Return to the Heart 683
  - 23.3c Blood Flow Through the Head and Neck 683
  - 23.3d Blood Flow Through the Thoracic and Abdominal Walls 689
  - 23.3e Blood Flow Through the Thoracic Organs and Spinal Cord 690
  - 23.3f Blood Flow Through the Gastrointestinal Tract 692
  - 23.3g Blood Flow Through the Posterior Abdominal Organs, Pelvis, and Perineum 695
  - 23.3h Blood Flow Through the Upper Limb 696
  - 23.3i Blood Flow Through the Lower Limb 699
- 23.4 Pulmonary Circulation 703
- 23.5 Review of Heart, Systemic, and Pulmonary Circulation 703
- 23.6 Aging and the Cardiovascular System 704
- 23.7 Blood Vessel Development 705
  - 23.7a Artery Development 705
  - 23.7b Vein Development 705
  - 23.7c Comparison of Fetal and Postnatal Circulation 706



## Chapter 24

### Lymphatic System 714

- 24.1 Functions of the Lymphatic System 715
- 24.2 Lymph and Lymphatic Vessels 716
  - 24.2a Lymphatic Capillaries 716
  - 24.2b Lymphatic Vessels 716
  - 24.2c Lymphatic Trunks 717
  - 24.2d Lymphatic Ducts 717

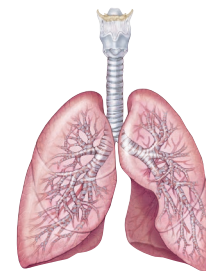


- 24.3 Lymphoid Cells 717
  - 24.3a Types and Functions of Lymphocytes 719
  - 24.3b Lymphopoiesis 723
- 24.4 Lymphoid Structures 725
  - 24.4a Lymphoid Nodules 725
  - 24.4b Lymphoid Organs 725
- 24.5 Aging and the Lymphatic System 731
- 24.6 Development of the Lymphatic System 731

## Chapter 25

### Respiratory System 737

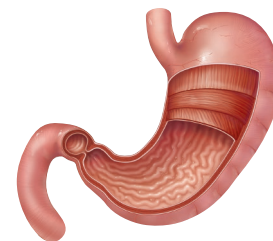
- 25.1 General Organization and Functions of the Respiratory System 738
  - 25.1a Respiratory System Functions 738
- 25.2 Upper Respiratory Tract 740
  - 25.2a Nose and Nasal Cavity 740
  - 25.2b Paranasal Sinuses 740
  - 25.2c Pharynx 740
  - 25.2d Larynx 743
- 25.3 Lower Respiratory Tract 745
  - 25.3a Trachea 747
  - 25.3b Bronchial Tree 748
  - 25.3c Respiratory Bronchioles, Alveolar Ducts, and Alveoli 750
- 25.4 Lungs 752
  - 25.4a Pleura and Pleural Cavities 752
  - 25.4b Gross Anatomy of the Lungs 752
  - 25.4c Blood Supply to and from the Lungs 753
  - 25.4d Lymphatic Drainage 753
- 25.5 Pulmonary Ventilation 756
- 25.6 Mechanics of Breathing 757
  - 25.6a Skeletal Muscles of Breathing 757
  - 25.6b Volume Changes in the Thoracic Cavity 757
- 25.7 Innervation of the Respiratory System 758
  - 25.7a Ventilation Control by Respiratory Centers of the Brain 758
- 25.8 Aging and the Respiratory System 761
- 25.9 Development of the Respiratory System 764



## Chapter 26

### Digestive System 769

- 26.1 General Structure and Functions of the Digestive System 770
  - 26.1a Digestive System Functions 770
- 26.2 Oral Cavity 771
  - 26.2a Cheeks, Lips, and Palate 771
  - 26.2b Tongue 772
  - 26.2c Salivary Glands 772
  - 26.2d Teeth 774
- 26.3 Pharynx 776

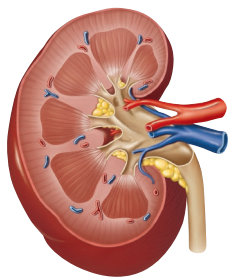


- 26.4 General Arrangement of Abdominal GI Organs 776
  - 26.4a Peritoneum, Peritoneal Cavity, and Mesentery 777
  - 26.4b General Histology of GI Organs (Esophagus to Large Intestine) 777
  - 26.4c Blood Vessels, Lymphoid Structures, and Nerve Supply 779
- 26.5 Esophagus 780
  - 26.5a Gross Anatomy 780
  - 26.5b Histology 780
- 26.6 The Swallowing Process 781
- 26.7 Stomach 783
  - 26.7a Gross Anatomy 783
  - 26.7b Histology 783
  - 26.7c Gastric Secretions 784
- 26.8 Small Intestine 787
  - 26.8a Gross Anatomy and Regions 787
  - 26.8b Histology 787
- 26.9 Large Intestine 789
  - 26.9a Gross Anatomy and Regions 789
  - 26.9b Histology 790
  - 26.9c Control of Large Intestine Activity 793
- 26.10 Accessory Digestive Organs 793
  - 26.10a Liver 793
  - 26.10b Gallbladder 796
  - 26.10c Biliary Apparatus 796
  - 26.10d Pancreas 797
- 26.11 Aging and the Digestive System 799
- 26.12 Development of the Digestive System 799
  - 26.12a Stomach, Duodenum, and Omenta Development 799
  - 26.12b Liver, Gallbladder, and Pancreas Development 799
  - 26.12c Intestine Development 801

## Chapter 27

### Urinary System 806

- 27.1 General Structure and Functions of the Urinary System 807
- 27.2 Kidneys 809
  - 27.2a Gross and Sectional Anatomy of the Kidney 809
  - 27.2b Blood Supply to the Kidney 810
  - 27.2c Innervation of the Kidney 812
  - 27.2d Nephrons 812
  - 27.2e Collecting Tubules and Collecting Ducts: How Tubular Fluid Becomes Urine 816
  - 27.2f Juxtaglomerular Apparatus 817

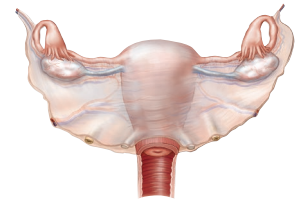


- 27.3 Urinary Tract 817
  - 27.3a Ureters 817
  - 27.3b Urinary Bladder 819
  - 27.3c Urethra 821
  - 27.3d Micturition 822
- 27.4 Aging and the Urinary System 823
- 27.5 Development of the Urinary System 824
  - 27.5a Kidney and Ureter Development 824
  - 27.5b Urinary Bladder and Urethra Development 824

## Chapter 28

### Reproductive System 830

- 28.1 Comparison of the Female and Male Reproductive Systems 831
  - 28.1a Perineum 831
- 28.2 Anatomy of the Female Reproductive System 832
  - 28.2a Ovaries 832
  - 28.2b Uterine Tubes 839
  - 28.2c Uterus 841
  - 28.2d Vagina 843
  - 28.2e External Genitalia 844
  - 28.2f Mammary Glands 845
- 28.3 Anatomy of the Male Reproductive System 849
  - 28.3a Scrotum 849
  - 28.3b Spermatic Cord 851
  - 28.3c Testes 851
  - 28.3d Ducts in the Male Reproductive System 854
  - 28.3e Accessory Glands 855
  - 28.3f Semen 856
  - 28.3g Penis 857
- 28.4 Aging and the Reproductive Systems 858
- 28.5 Development of the Reproductive Systems 860
  - 28.5a Genetic Versus Phenotypic Sex 860
  - 28.5b Formation of Indifferent Gonads and Genital Ducts 860
  - 28.5c Internal Genitalia Development 862
  - 28.5d External Genitalia Development 862



Appendix A: Answers A-1

Glossary G-1

Index I-1

## What Makes This Book Special?

**H**uman anatomy is a fascinating field with many layers of complexity. The subject is difficult to teach, and students can often be overwhelmed by its massive amount of material. Our goal in writing *Human Anatomy* was to create a textbook that guides students on a clearly written and expertly illustrated beginner's path through the human body. For all six editions it has been of paramount importance to make this book enjoyable to read, easy to understand, pedagogically efficient, and visually engaging. The following pages highlight the enhancements we've made to the sixth edition, as well as the hallmark features that define this book.

### I New to the Sixth Edition

New research findings, shifting terminology, technological advancements, and the evolving needs of students and instructors in the classroom require textbook authors to continually monitor and revise their content. Throughout the sixth edition, changes have been made to incorporate the latest information, update terminology, and improve wording to make discussions easier for students to read and understand. Highlights of these revisions are as follows.

#### Global Changes

**The Sixth Edition received some global changes to increase student understanding and success.**

- Additional Learning Strategies are added to each chapter, and are consecutively numbered, for easier reference
- All major concepts are addressed by a measurable Learning Objective
- Data from McGraw-Hill's LearnSmart program was used to clarify and edit text in areas where students most need support
- *What Did You Learn?* questions are revised to be more challenging and provide more active learning experiences such as drawing, preparing flowcharts, or making tables of concepts
- When possible, images or photos are added to most *Clinical Views* and *Learning Strategies*
- Each End of Chapter section is extensively revised, including:
  - *Challenge Yourself* section now includes a prompt for students to actively write or type their answers in a separate document to reinforce learning before checking their answers
  - *Challenge Yourself* questions are aligned to cover all chapter Learning Objectives
  - *Multiple Choice* and *Content Review* questions are edited to be more challenging and to review more global aspects
  - All chapters now have three *Developing Critical Reasoning* questions

In addition to these changes, all chapters were thoroughly edited to respond to reviewers' comments and suggestions. Chapter-specific changes are as follows:

xii

#### Chapter 1 A First Look at Anatomy

- New Clinical View 1.1: Clinicians' Use of Scientific Method
- New Clinical View 1.2: Etiology (Causes) and Pathogenesis (Development) of Disease
- Modified section 1.4e to clarify discussion of pelvic brim
- Edited Clinical View 1.3: Medical Imaging Procedures
- Revised figures: 1.1a, 1.1b, 1.4, 1.5
- Revised tables: 1.1, 1.4

#### Chapter 2 The Cell: Basic Unit of Structure and Function

- New Learning Strategy 2.2 on receptors and ligands
- Modified section 2.1b to clarify discussion of the general cell function of reproduction
- Edited Clinical View 2.3: Adrenoleukodystrophy (ALD) to include more recent treatment
- Adapted Clinical View 2.5: Characteristics of Cancer Cells to include an image of a dividing cervical cancer cell
- Revised figures: 2.1, 2.5, 2.9–2.13, 2.15, 2.19, 2.20
- Revised table 2.2

#### Chapter 3 Embryology

- New Clinical View 3.7: Preterm (Premature) Birth
- Revised Clinical View 3.6 to include information on both Amniocentesis and Chorionic Villus Sampling
- Edited Clinical View 3.5: Congenital Malformations
- Edited text in sections 3.2 (discussion of fertilization), 3.3 (clarified concept of capacitation), 3.4g (clarified peak development period)
- Revised figures: 3.1, 3.3, 3.5, 3.6, 3.7
- Revised tables: 3.2, 3.3, 3.4

#### Chapter 4 Tissue Level of Organization

- Revised Clinical View 4.1: Stem Cells
- Edited Clinical View 4.2: What Are You Planning to Do with Your Baby's Umbilical Cord?
- Modified Clinical View 4.4: Gangrene
- Edited Clinical View 4.5: Tissue Transplantation
- Modified section 4.1a discussion on polarity to include apical surface modifications
- Adapted section 4.1f to change the discussion order of secretion types
- Edited section 4.4a to clarify use of terms *involuntary* and *autorhythmic*
- Revised figures: 4.1b, 4.2, 4.4, 4.7, 4.8
- Revised tables: 4.1, 4.11, 4.13

#### Chapter 5 Integumentary System

- New Learning Strategy 5.2 and accompanying photo comparing dermal papillae and epidermal ridges to egg crate foam

- Edited section 5.1b on metabolic regulation
- Revised section 5.2a description of stratum spinosum
- Modified section 5.5 to clarify discussion of epidermal derivatives
- Removed Clinical View 5.3 on dermatoglyphics, and incorporated selected information into the text
- Added new photos for selected Clinical View boxes
- Clinical View 5.6: Treatments for Aging Skin is updated to include information about dermal fillers, with a new photo of a Botox treatment
- Revised figures: 5.3, 5.4, 5.9, 5.10
- Revised tables: 5.3, 5.4

### Chapter 6 Cartilage and Bone

- Enhanced Clinical View 6.3: Achondroplastic Dwarfism with the inclusion of a photo
- Revised Clinical View 6.5: Bone Scans
- Edited Clinical View 6.6: Osteoporosis
- Revised figures: 6.4, 6.8, 6.9, 6.12, 6.13, 6.16

### Chapter 7 Axial Skeleton

- Section 7.1 discussion of basal view of the skull edited
- Clinical View 7.3: Spinal Curvature Abnormalities was adapted to incorporate the terms *hyperkyphosis* and *hyperlordosis* to describe abnormal curvatures
- Modified Clinical View 7.4: Herniated Discs
- Revised figures: 7.7, 7.9, 7.15, 7.23

### Chapter 8 Appendicular Skeleton

- Adapted Clinical View 8.1: Fracture of the Clavicle to add an illustration
- Modified Clinical View 8.2: Colles Fracture to add an illustration
- Expanded Clinical View 8.4: Pott Fracture to include an illustration
- Revised figures: 8.2, 8.4, 8.9, 8.10, 8.11

### Chapter 9 Articulations

- New Learning Strategy 9.2 on gomphosis
- New Learning Strategy 9.3 relating to the movements at selected joints
- Edited Clinical Views 9.1–9.9 to be more concise; Clinical View 9.9: Arthritis contains updated treatment information; new photos are added to Clinical Views 9.1 and 9.6; several photos in other Clinical Views were replaced
- Removed previous Clinical View on Joint Replacement; pertinent text is now included in section 9.6 (disease and aging of the joints)
- Revised discussions in section 9.4a (general anatomy of synovial joints) on cartilage, bursae throughout the body, and Hilton’s law with regard to innervation of joints
- Edited discussion of glenohumeral joint in section 9.5b to emphasize that it is the muscles, not the ligaments, that provide support to the joint
- Expanded discussion of the elbow joint in section 9.5b to include discussion on Tommy John surgery to emphasize the importance of the ulnar collateral ligament in this joint
- Revised figures: 9.7, 9.11
- Edited table 9.2, figure 9.7, and the text to emphasize that hyperextension is a movement beyond the normal range of motion

- Edited tables 9.3–9.5 to ensure consistent discussion of movement

### Chapter 10 Muscle Tissue and Organization

- New Learning Strategy 10.1 on the connective tissue components of muscle
- Expanded Learning Strategy 10.3 to include a figure
- New Learning Strategy 10.4 on motor unit recruitment
- Updated Clinical View 10.1: Tendonitis
- Enhanced Clinical View 10.3: Muscular Paralysis and Neurotoxins with a figure
- Revised Clinical View 10.5: Anabolic Steroids and Other Performance-Enhancing Compounds
- Updated Clinical View 10.6: Neuromuscular Diseases
- Enhanced our discussion of levers in section 10.7 by adding text and a figure

### Chapter 11 Axial Muscles

- Modified Learning Strategy 11.1
- Extensively edited Clinical View 11.2: Strabismus, including new photos
- Edited section 11.15, figure 11.15, and table 11.12 to replace the outdated reference to “urogenital diaphragm” with the names of the muscles composing this structure
- Revised figure 11.15
- Revised tables: 11.8, 11.10, 11.12

### Chapter 12 Appendicular Muscles

- Added photo to Clinical View 12.1: Paralysis of the Serratus Anterior Muscle (“Winged Scapula”)
- Removed Clinical View 12.5: Anatomic Snuffbox
- Modified Clinical View 12.5: Thigh Muscle Injuries to include figure
- Expanded Clinical View 12.6: Plantar Fasciitis to include figure
- Updated Clinical View 12.7: Shin Splints and Compartment Syndrome
- Enhanced Learning Strategy 12.5 with a new figure
- Edited section 12.1b to include discussion of short head of biceps brachii
- Updated terminology: actions versus functions of muscles; intermuscular septum; radial and ulnar deviation
- Edited section 12.2c to note the variability of presence of fibularis tertius
- Revised figures: 12.1, 12.2, 12.4, 12.5, 12.16
- Revised tables: 12.1, 12.2, 12.4, 12.6, 12.8

### Chapter 13 Surface Anatomy

- New *What Did You Learn?* section at the end of section 13.1
- New Learning Strategy 13.2 to help distinguish the anterior and lateral cervical regions of the neck
- New Learning Strategy 13.3 to help students remember which side of the lower limb originates the small and great saphenous veins
- Modified section 13.2 to discuss six regions of the face
- Clinical View 13.1: Lip Color as a Diagnostic Tool includes a new photo
- Updated section 13.3 and figure 13.2 the discussion on the regions of the neck, using the *Terminologia Anatomica*-approved terms *anterior*, *lateral*, and *posterior cervical regions of the neck*; the terms *anterior triangle* and *posterior triangle* are replaced

- Revised section 13.6d (foot) to clarify discussion on where to take the pulse of the dorsalis pedis artery

#### Chapter 14 Nervous Tissue

- New Learning Strategy 14.1 on functions of dendrites and axons
- New Learning Strategy 14.3 on myelin
- Significantly revised Clinical View 14.1: Neuroplasticity and Neurogenesis, including differentiation between the CNS and the PNS
- Enhanced Clinical View 14.2: Tumors of the Central Nervous System with a new image
- Added new Clinical View 14.3: Nervous System Disorders Affecting Myelin
- Revised Clinical View 14.4: Treating Spinal Cord Injuries
- Modified Clinical View 14.5: Amyotrophic Lateral Sclerosis
- Updated Clinical View 14.6: Neural Tube Defects
- Edited section 14.2a to update discussion on anaxonic neurons
- Edited section 14.2b to include current information on astrocyte function, and neuron-to-glial-cell ratios
- Edited section 14.6a
- Edited section 14.7 to use the term *neuronal circuits* instead of *neuronal pools*, and to clarify examples
- Revised figures: 14.10, 4.12
- Revised tables: 14.1, 14.4

#### Chapter 15 Brain and Cranial Nerves

- Modified all Clinical Views, with new photos added when appropriate
- Clarified section 15.2 regarding the meninges and the falx cerebri
- Retitled Clinical View 15.1 Meningitis and Encephalitis, and included information on both for comparison, as some people confuse the two ailments
- New Learning Strategy 15.2 notes the cerebral lobes share the same name as the skull bone that overlies each lobe
- Edited and updated Section 15.3b discussion of sensory homunculus per medical neuroscience research to state there is extensive overlap of body regions in this structure (and thus it is not as precise as the motor homunculus)
- Extensively updated Clinical View 15.5 to discuss functional brain regions and provide up-to-date information from the Human Connectome Project about updated brain maps. It includes new photos from the Human Connectome Project.
- Removed section 15.3b and figure 15.11: discussion and portrayal of gnostic area, due to debate by neuroscientists about this region's borders and functions
- Edited, clarified, and updated section 15.3d and table 15.5: discussion on cerebral nuclei per latest neuroscience research
- New Learning Strategy 15.3 to help the reader remember the functions of the superior and inferior colliculi
- Revised section 15.5 (brainstem)
- Updated section 15.6 (cerebellum) to discuss additional non-motor functions of the cerebellum
- New Learning Strategy 15.4 on the cerebellar peduncle and how it connects to the brainstem
- Revised section 15.7 (limbic system) to include information about neurogenesis in the hippocampus
- Revised figures: 15.11, 15.13, 15.19, 15.20, 15.22

#### Chapter 16 Spinal Cord and Spinal Nerves

- Significantly updated Clinical View 16.1: Lumbar Puncture and Epidural Injection to include the similarities and differences between the two
- Updated terminology in Clinical View 16.2: Shingles (Herpes Zoster)
- Revised Clinical View 16.3: Brachial Plexus Injuries text, with an added figure
- Enhanced Clinical View 16.4: Sacral Plexus Nerve Injuries with a new figure
- New Learning Strategy 16.3 distinguishes vertebral foramina from intervertebral foramina
- Expanded section 16.4g to include a paragraph on sural nerves
- Modified section 16.5b to change terminology from *Golgi tendon reflex* to *tendon reflex*
- Revised figures: 16.2, 16.3; removed figure 16.4
- Revised tables: 16.3, 16.4

#### Chapter 17 Pathways and Integrative Functions

- New Learning Strategy 17.1 distinguishes between a tract and a pathway
- Revised section 17.1 based on recent research on the sensory homunculus
- New Learning Strategy 17.3 on location of sensory pathways and their common primary neuron—posterior root ganglion
- Clarified section 17.2a discussion of sensory pathways
- New Learning Strategy 17.4 distinguishes medial pathway from lateral pathway
- Updated Clinical View 17.1: Cerebrovascular Accident to include information about transient ischemic attacks
- Retitled Clinical View 17.2 as Epilepsy, Lobectomy, and Hemispherectomies, with updated text
- Updated Clinical View 17.6: Alzheimer Disease: The “Long Goodbye”
- Revised figures: 17.9, 17.10, 17.12

#### Chapter 18 Autonomic Nervous System

- New Learning Strategy 18.2 on functions of parasympathetic versus sympathetic nervous system
- New Learning Strategy 18.3 on remembering splanchnic nerves
- Added new Clinical View 18.1: Autonomic Nervous System and Cardiovascular Disease
- Enhanced Clinical View 18.2: Raynaud Syndrome with a new figure
- Expanded Clinical View 8.4: Autonomic Dysreflexia expanded to include bladder/bowel care in spinal cord injuries and a new figure
- Edited section 18.3 reference to the PNS decreasing force of contraction in the heart
- Revised section 18.5c on lack of ANS influence on skeletal muscle blood vessels, and to discuss the receptors for the ANS
- Revised figures: 18.1, 18.3, 18.4, 18.5, 18.7, 18.8, 18.9
- Revised tables: 18.1, 18.2, 18.3, 18.4, 18.5

#### Chapter 19 Senses: General and Special

- Reordered and edited sections 19.3 and 19.4 to discuss olfaction prior to gustation
- Added photos to selected Learning Strategies

- Clarified discussion in section 19.1a is edited on tonic vs. phasic receptors
- Clarified text in section 19.2 contains clarified text on encapsulated tactile receptors
- New Learning Strategy 19.2 highlights similarities between olfactory and gustation receptors
- New Learning Strategy 19.3 helps to recall the differences between rods and cones
- New Learning Strategy 19.4 details that semicircular ducts detect angular movements of the head
- New Clinical View 19.9: Are Earbuds Bad for Your Health?
- Revised figures: 19.2, 19.5, 19.6 (previously 19.8), 19.11, 19.12, 19.13, 19.14, 19.17, 19.26
- Revised table 19.4

### Chapter 20 Endocrine System

- Enhanced Learning Strategy 20.1 with a new figure
- Updated Clinical View 20.1: Disorders of Growth Hormone Secretion
- Modified Clinical View 20.2: Hypophysectomy to include figure
- Clinical View 20.3: Disorders of Thyroid Hormone Secretion includes updated photos
- Edited section 20.3a to clarify the portal system and what it is in general before discussing the specific portal system
- Reordered and edited section 20.3a discussion of mammatropic cells and prolactin
- Edited section 20.9a to clarify renin secretion
- Revised figures: 20.1, 20.6, 20.10, 20.12, 20.13, 20.14, 20.15; removed figure 20.13
- Revised tables: 20.1, 20.2, 20.3, 20.4, 20.6, 20.7, 20.8

### Chapter 21 Blood

- Edited section 21.1b (functions of blood) to clarify discussion on pH, and movement of fluid and nutrients
- Added new section 21.2b (other solutes in plasma) and expanded complement information in table 21.1
- Added new photos to selected Clinical Views
- Modified Clinical View 21.2 to focus on anemia; includes a new photo
- New Clinical View 21.4: Whole Blood versus Plasma Donations
- Edited section 21.3b (leukocytes) and section 21.3c (platelets)
- Included the embryonic period in section 21.4 (hematopoiesis)
- Added discussion in section 21.4 about alternative models for hematopoiesis
- Revised figures: 21.7, 21.10
- Revised table 21.1

### Chapter 22 Heart

- New Learning Strategy 22.2 on coronary circulation
- New Learning Strategy 22.4 on pressure and blood flow
- Enhanced Clinical View 22.1: Pericarditis with a new figure
- Revised Clinical View 22.4: Angina Pectoris and Myocardial Infarction to include a figure
- Edited section 22.1c to clarify the role of serous fluid in the pericardial cavity
- Modified sections 22.2b and 22.2c for clarity

- Revised section 22.4b's discussion on gap junctions and desmosomes
- Edited terminology from *isovolumetric* to *isovolumic* in section 22.6a and figure 22.14
- Revised figures: 22.1, 22.2, 22.5, 22.9, 22.14
- Revised table 22.2

### Chapter 23 Vessels and Circulation

- Modified and repositioned Learning Strategy 23.3 to before section 23.3a, where the named vessels are first discussed
- Added examples to section 23.1 (anatomy of blood vessels) to illuminate the difference between arterial and venous anastomoses
- Revised section 23.1a to explain the difference between arteries and veins
- Clarified section 23.1b regarding vasoconstriction of all artery types to varying degrees
- Edited the discussion of section 23.1c (capillaries) about precapillary sphincters and capillary beds
- Revised section 23.3 to include a new section on blood flow through the spinal cord
- New Learning Strategy 23.5 helps recall where the great saphenous vein is located
- Rewrote and expanded section 23.6
- Revised figures: 23.4, 23.8

### Chapter 24 Lymphatic System

- Terminology is modified throughout the chapter: *lymphoid* is used to reference organs, structures, and cells; *lymphatic* is used when referring to the system, vessels, ducts, trunks, capillaries, and movement of lymph
- New Learning Strategy 24.1 on movement of lymph into capillaries
- New Learning Strategy 24.3 on functions of different types of lymphocytes
- Edited section 24.2c and section 24.3a
- Replaced photos in several Clinical View boxes
- Revised figures: 24.1, 24.5, 24.6, 24.7, 24.8, 24.10

### Chapter 25 Respiratory System

- Edited/corrected the discussion in sections 25.1, 25.2 and 25.3, in table 25.2, and in selected figures to clarify the division between the upper and lower respiratory tracts, so the larynx is included with discussion of the upper respiratory tract
- Larynx (previously section 25.3a) moved to section 25.2d (so it is grouped with other upper respiratory tract structures)
- New photos added to Learning Strategies and Clinical Views, when appropriate
- In section 25.2b, more detail added regarding the function of the paranasal sinuses
- Revised Clinical View 25.3 to focus on aspirated bodies and the Heimlich maneuver; includes new photo of how to perform the Heimlich maneuver; discussion of bronchoscopy removed as this clinical procedure is no longer commonly used
- Expanded section 25.3c (bronchial tree) to explain why less cartilage is needed in the bronchial tree compared to the trachea, and that bronchoconstriction and bronchodilation are controlled by the ANS
- Modified sections 25.6a and 25.7a
- Revised figures: 25.1, 25.4, 25.7, 25.8, 25.9, 25.10



### Chapter 26 Digestive System

- New Learning Strategy 26.1 on mixing/segmentation
- Revised section 26.1a to employ the term *segmentation*
- Edited section 26.2c to update secretion types in salivary glands
- Edited sections 26.4a and 26.4b
- Replaced photos in Clinical Views 26.2, 26.3, 26.4, 26.5, 26.6
- Edited text in Clinical View 26.5: Gallstones (Cholelithiasis) to distinguish between cholelithiasis and choledocholithiasis
- Enhanced Clinical View 26.8: Intestinal Disorders with a new figure
- Revised figures: 26.6, 26.11, 26.21

### Chapter 27 Urinary System

- New Learning Strategy 27.1 on the main function of the kidneys
- New Learning Strategy 27.2 to help visualize the retroperitoneal nature of the kidneys
- Edited section 27.2d (nephrons) and table 27.2 to clarify that nutrients normally are reabsorbed at the proximal convoluted tubule
- New Learning Strategy 27.4 uses the analogy of a conveyor belt to explain filtration, secretion, and reabsorption
- New Learning Strategy 27.5 to help recall that aldosterone helps us retain sodium

- Updated terminology in section 27.2f (juxtaglomerular apparatus) using *granular cells* to replace *juxtaglomerular cells*
- New Learning Strategy 27.6 on how to ID transitional epithelium
- Edited section 27.3c discussion of external urethral sphincter to remove reference to the outdated term *urogenital diaphragm*
- Revised figures: 27.7, 27.8, 27.10, 27.11

### Chapter 28 Reproductive System

- Added subheads to better organize ovarian cycle phase discussion
- Updated section 28.2a for more current discussion of the follicular phase
- Edited section 28.2c for easier readability
- Updated Clinical View 28.1 to add a figure
- Replaced photos in Clinical Views 28.2, 28.5
- Updated Clinical View 28.2: Cervical Cancer with current information
- Added figures to Clinical View 28.3: Endometriosis, Clinical View 28.6: Benign Prostatic Hyperplasia and Prostate Cancer, and Clinical View 28.8: Sexually Transmitted Infections
- Updated Clinical View 28.4: Contraception Methods
- Modified Clinical View 28.5: Breast Cancer
- Revised figures: 28.4, 28.6, 28.11, 28.13, 28.16

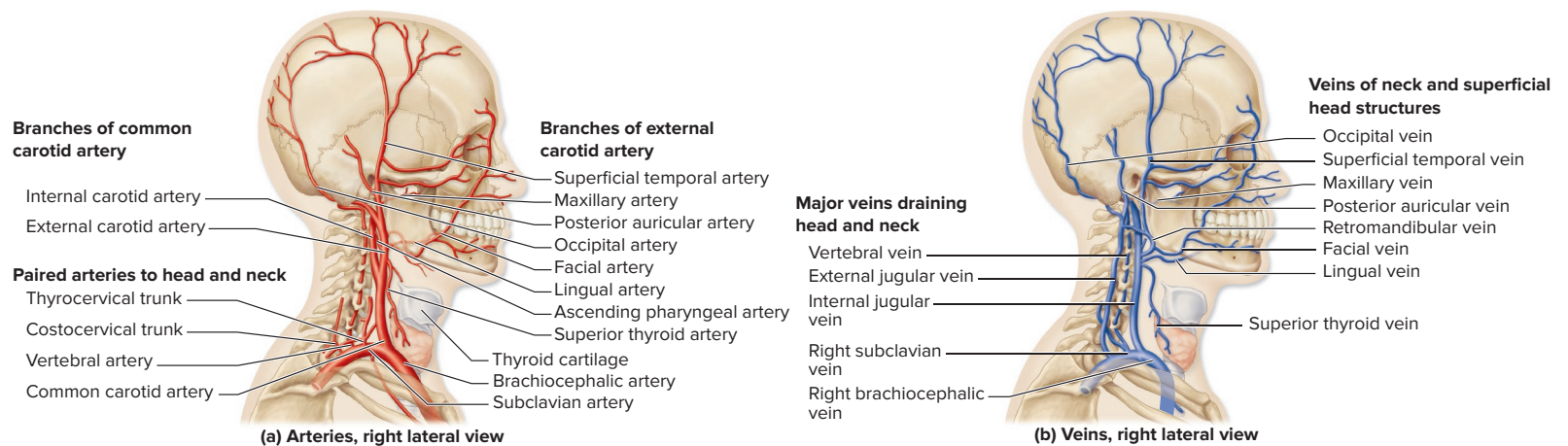
# Themes and Distinctive Topic Approaches

**T**hrough our teaching experience, we have developed a few approaches that really seem to help students grasp certain topics or spark their interest. Thus, we have tried to incorporate these successful ideas from our own courses into our book.

- **Embryology.** Learning about embryologic events can increase understanding of the adult anatomy. For this reason, chapter 3, Embryology, appears early in the book. In addition, “systems embryology” sections in each systems chapter (e.g., integumentary system, digestive system) provide a brief but thorough overview of the developmental processes for that particular system.
- **Forensic Anthropology.** Forensic examples are a great way to reinforce learning, and students enjoy the “real-life” application of anatomic knowledge in forensic analysis. The skeletal system chapters (6–9) feature discussions on topics such as determining age of death by evaluating epiphyseal plates and the pubic symphysis, and determining sex by noting differences in the skull and pelvis.
- **Surface Anatomy.** To best serve our audience, we have dedicated a full chapter (13) to surface anatomy. This chapter

contains beautiful photographs and clear, concise text as well as numerous Clinical Views that illustrate the importance of surface anatomy landmarks and how they are used daily in health care.

- **Nervous System.** In order to understand the workings of the nervous system, it is best to learn how the brain controls all aspects of the nervous system. Thus, in this text we examine the brain first, followed by a chapter comparing its similarities, differences, and relationships to the spinal cord. It seemed appropriate to use central nervous system terminology to describe the brain first and then the spinal cord. Additionally, because the nuclei of the cranial nerves are housed within the brain, we felt it made more sense to present the cranial nerves along with the brain.
- **Arteries and Veins.** Arteries and veins are covered in unison by region. For example, we present the arteries and veins of the upper limb together. This approach emphasizes to students that the arteries often have corresponding veins and that both are responsible for the blood flow in a general region.



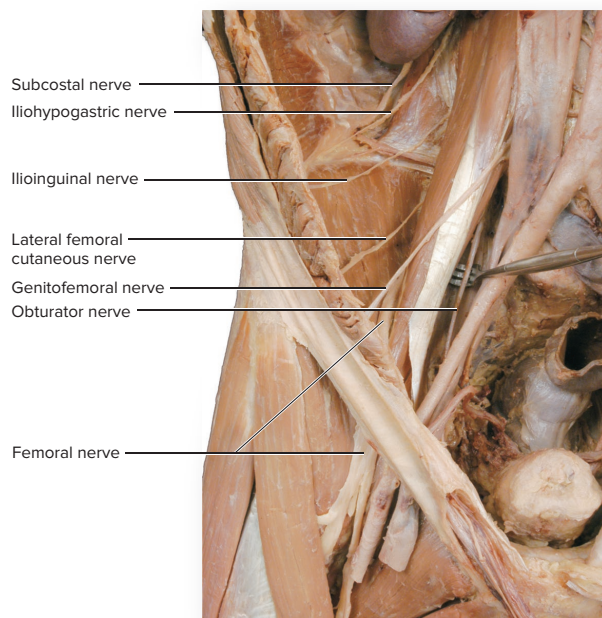
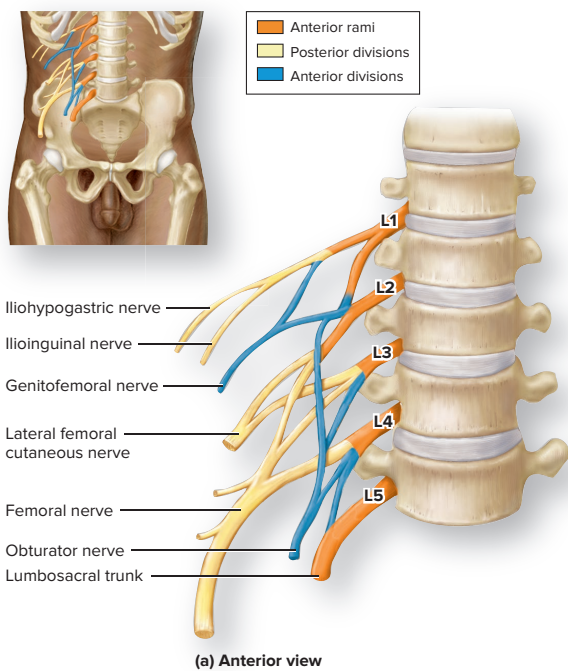
# Accurate and Engaging Illustrations

**B**ecause anatomy is a visual subject, quality illustrations are crucial to understanding and retention. The brilliant illustrations in *Human Anatomy* bring the study of anatomy to life! Drawn by a team of medical illustrators, all figures have been carefully rendered to convey realistic, three-dimensional detail. Each drawing has been meticulously reviewed for accuracy and consistency, and precisely labeled to

coordinate with the text discussions. *Human Anatomy* also features a beautiful collection of cadaver dissection images, bone photographs, surface anatomy shots, and histology micrographs. These detailed images capture the intangible characteristics of human anatomy that can only be conveyed in human specimens, and help familiarize students with the appearance of structures they will encounter in lab.

## View Orientation

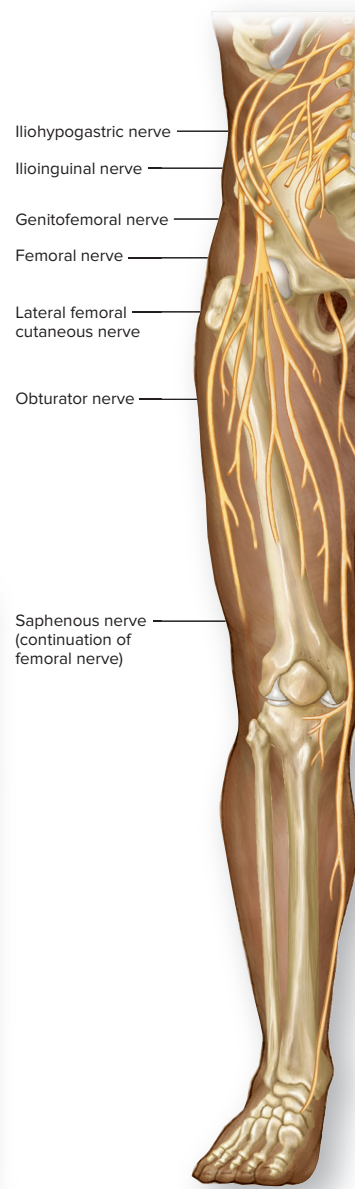
Reference diagrams clarify the view or plane an illustration represents.



(b) ©McGraw-Hill Education/Christine Eckel, photographer

## Color Coding

Many illustrations use color coding to organize information and clarify concepts for visual learners.

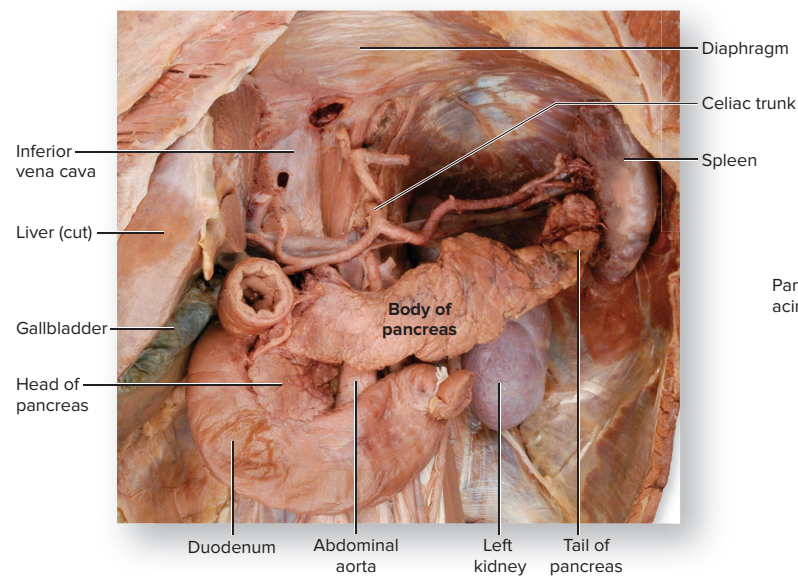
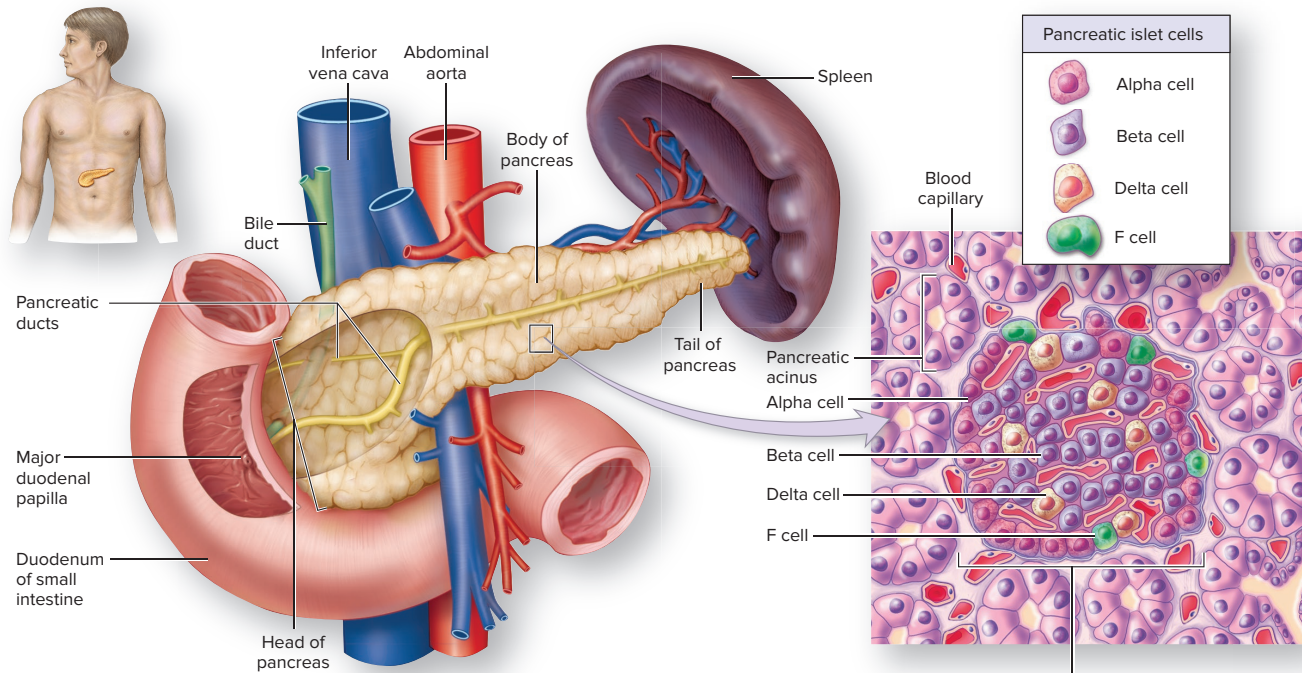


## Multilevel Perspective

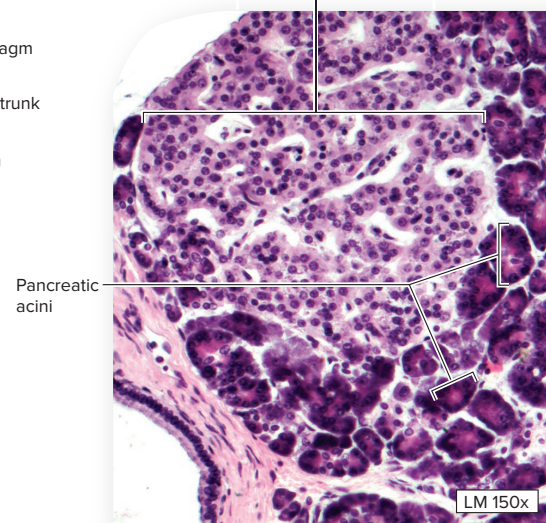
Illustrations depicting complex structures connect macroscopic and microscopic views to show the relationships between increasingly detailed drawings.

## Complementary Views

Drawings paired with photographs enhance visualization of structures. Labels on art and photos mirror each other whenever possible, making it easy to correlate structures between views.



(a) Anterior gross view



(b) Microscopic view

(a) ©McGraw-Hill Education/Christina Eckel, photographer;  
 (b) ©McGraw-Hill Education/Alvin Telsler, photographer

## Cadaver Dissections

Expertly dissected specimens are preserved in richly colored photos that reveal incredible detail. Many unique views show relationships between anatomic structures from a new perspective.

## Histology Micrographs

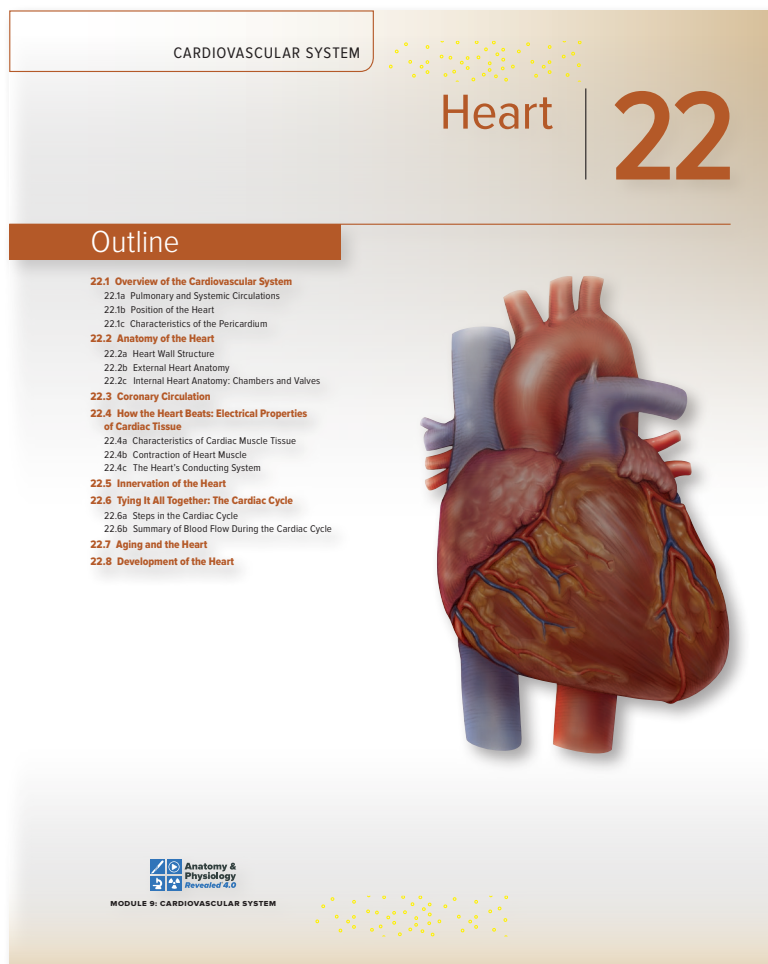
Light micrographs, as well as scanning and transmission electron micrographs, are used in conjunction with illustrations to present a true picture of microscopic anatomy. Magnifications provide a reference point for the sizes of the structures shown in the micrographs.

# Helpful Pedagogical Tools

**H**uman Anatomy is built around a pedagogical framework designed to foster retention of facts and encourage the application of knowledge that leads to understanding. The learning aids in this book help organize studying, reinforce learning, and promote critical-thinking skills.

## Chapter Outline

Each chapter begins with an outline that provides a quick snapshot of the chapter contents and organization. Headings are numbered throughout the chapter for easy reference.



## Learning Objectives

Numbered learning objectives at the beginning of each section help focus attention on critical information. Online question banks are correlated with these objectives.

## 22.1 Overview of the Cardiovascular System

### ✓ Learning Objectives

1. Identify and describe the basic features of the cardiovascular system.
2. Describe and trace the general patterns of the pulmonary and systemic circulations.
3. Identify and describe the position and location of the heart.
4. Discuss the structure and function of the pericardium.

## What Do You Think?

These critical thinking questions actively engage students in application or analysis of the chapter material and encourage students to think more globally about the content. Answers to **What Do You Think?** questions are given at the end of each chapter, allowing students to evaluate the logic used to solve the problem.

## WHAT DO YOU THINK?

- 2 Have you ever noticed that most of the salt you buy in the grocery store is labeled as “iodized”? Why is iodine added to our salt?

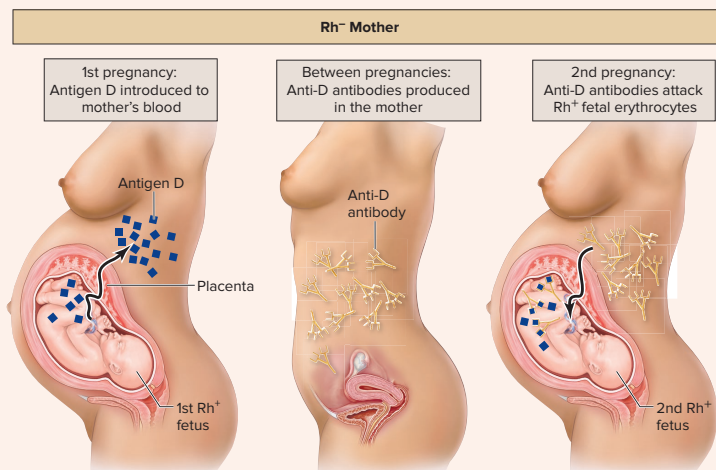


### Clinical View 21.3

#### Rh Incompatibility and Pregnancy

The potential presence of anti-D antibodies is especially important in pregnant women who are Rh negative and have an Rh positive fetus. An Rh incompatibility may result during the pregnancy if the mother has previously been exposed to Rh positive blood (such as can occur with a previously carried Rh positive fetus, typically at the time of childbirth). As a result of the prior exposure, the mother has anti-D antibodies that may cross the placenta and destroy the fetal erythrocytes, resulting in severe illness or death. The illness that occurs in the newborn is called **hemolytic disease of the newborn (HDN)**, or *erythroblastosis fetalis*. The newborn typically presents with *anemia* and *hyperbilirubinemia* (increased bilirubin in the blood) due to erythrocyte destruction. In severe cases, the infant may develop heart failure and must be given a blood transfusion to survive.

Giving a pregnant Rh negative woman special immunoglobulins (e.g., RhoGAM) between weeks 28–32 of her pregnancy and at birth prevents the mother from developing anti-D antibodies. Specifically, these immunoglobulins bind to fetal erythrocyte surface antigens—and in so doing, prevent the mother's immune system from recognizing Rh antigens and being stimulated to produce anti-D antibodies.



|              | Mother Rh Blood Types |   | Fetus Rh Blood Types |  |
|--------------|-----------------------|---|----------------------|--|
|              | Pregnancy #1          | Pregnancy #2                                  | Pregnancy #1         | Pregnancy #2   |
| Blood type   | Rh negative           | Rh negative                                   | Rh positive          | Rh positive  |
| Erythrocytes | No antigen D<br>      | No antigen D<br>                              | Antigen D<br>        | Antigen D<br>  |
| Plasma       | No anti-D antibodies  | Anti-D antibodies (due to prior exposure)<br> | No anti-D antibodies | Anti-D antibodies from mother cross placenta and attack fetal erythrocytes causing <b>hemolytic disease of the newborn</b> |

Hemolytic disease of the newborn.

### Clinical View

Sometimes an example of what can go wrong in the body helps crystallize understanding of the “norm.” **Clinical Views** provide insights into health or disease processes. These essays expand upon topics covered in the text and provide relevant background information for students pursuing health-related careers.

In contrast to the ABO blood group, where antibodies may be found in the blood even without prior exposure to a foreign antigen, antibodies to the Rh factor termed **anti-D antibodies** appear in the blood only when an Rh negative individual is exposed to Rh positive blood. This exposure to Rh positive blood most often occurs as a result of an inappropriate blood transfusion. Therefore, individuals who are Rh positive never exhibit anti-D antibodies, because they possess the Rh antigen on their erythrocytes. Only individuals who are Rh negative can exhibit anti-D antibodies, and that can occur only after exposure to Rh antigens.

The ABO and Rh blood types are usually reported together. For example, types AB and Rh<sup>+</sup> together are reported as AB<sup>+</sup>. However,

remember that ABO and Rh blood types are independent of each other, and neither of them interacts with or influences the presence or activities of the other group.

#### WHAT DID YOU LEARN?

- Why does an erythrocyte lack cellular organelles, and how is this related to its life span?
- How do transferrin and ferritin participate in recycling erythrocyte components after the cells break down?
- Should a person with blood type A donate blood to a person with blood type AB? Why or why not?

### What Did You Learn?

Review questions at the end of each section prompt students to test their comprehension of key concepts. These mini self-tests help students determine whether they have a sufficient grasp of the information before moving on to the next section of the chapter.

### Learning Strategy 14.3

Recall from Section 2.3a: “Composition and Structure of Membranes” that the plasma membrane is composed of lipids and proteins. Similar to flattening and rolling up a tube of toothpaste to get the toothpaste out, the myelinating cell (neurolemmocyte or oligodendrocyte) is flattened and rolled up, leaving only the lipid bilayers of plasma membrane, which make the myelin.



Lawrence Manning/Getty Images

### Learning Strategy

Many anatomy instructors provide students with everyday analogies, mnemonics, and other useful tips to help them understand and remember the information. **Learning Strategy** boxes throughout each chapter offer tried-and-tested practical learning strategies that students can apply as they read. These tips are not just useful—they can also be fun!

# End-of-Chapter Tools

710



Chapter Twenty-Three Vessels and Circulation

## Clinical Terms

**edema** Noticeable swelling from fluid accumulation in body tissues. Edema most commonly occurs in the feet and legs, where it is referred to as peripheral edema.

**Korotkoff (kō-rōt kōf) sounds** Distinctive sounds heard through a stethoscope when taking a blood pressure reading, resulting from blood turbulence in the artery. The sounds are first

heard when the cuff pressure equals the systolic pressure and cease to be heard once the cuff has deflated past the diastolic pressure.

**vasculitis** (vas-kyū-lī-tis) Inflammation of any type of blood vessel. If only arteries are inflamed, the condition is called *arteritis*; if only veins are inflamed, it is called *phlebitis*.

## Chapter Summary

|                                      |  |
|--------------------------------------|--|
| <b>23.1 Anatomy of Blood Vessels</b> | <ul style="list-style-type: none"><li>Blood vessels form a closed supply system to transport oxygen and nutrients to body tissues, and remove waste products from these tissues.</li><li>Arteries conduct blood away from the heart; capillaries exchange gases, nutrients, and wastes with body tissues; and veins conduct blood to the heart.</li></ul> <p><b>23.1a Blood Vessel Tunics</b></p> <ul style="list-style-type: none"><li>The tunica intima (innermost layer) is composed of an endothelium, a basement membrane, and a layer of areolar connective tissue. It also may contain an internal elastic lamina.</li><li>The tunica media (middle layer) is composed of smooth muscle and also may have an external elastic lamina. This is the largest tunic in an artery.</li><li>The tunica externa (outermost layer) is composed of areolar connective tissue and adipose connective tissue. This is the largest tunic in a vein.</li><li>Capillaries have a tunica intima, composed of an endothelial layer and a basement membrane only.</li></ul> <p><b>23.1b Arteries</b></p> <ul style="list-style-type: none"><li>Elastic arteries have the largest diameter and the greatest proportion of elastic fibers in their walls.</li><li>Muscular arteries are medium-sized arteries with more smooth muscle and fewer elastic fibers to ensure vasodilation and vasoconstriction.</li><li>Arterioles are the smallest arteries.</li></ul> <p><b>23.1c Capillaries</b></p> <ul style="list-style-type: none"><li>Capillaries, the smallest blood vessels, connect arterioles with venules. Gas and nutrient exchange occurs in the capillaries.</li><li>The three types of capillaries are continuous capillaries, fenestrated capillaries, and sinusoids.</li></ul> <p><b>23.1d Veins</b></p> <ul style="list-style-type: none"><li>Venules are small veins that merge into larger of the body's blood at rest.</li><li>One-way valves prevent blood backflow in vein.</li></ul> |
| <b>23.2 Blood Pressure</b>           | <ul style="list-style-type: none"><li>Blood pressure is the force exerted by the blood ventricular contraction, and diastolic pressure.</li></ul>  |
| <b>23.3 Systemic Circulation</b>     | <ul style="list-style-type: none"><li>The systemic circulation conducts oxygenated</li></ul> <p><b>23.3a General Arterial Flow Out of the Heart</b></p> <ul style="list-style-type: none"><li>The ascending aorta gives off the left and right</li><li>The aortic arch has three branches: the brachio</li><li>The descending thoracic aorta extends several</li><li>The descending abdominal aorta bifurcates in</li><li>arteries.</li></ul> <p><b>23.3b General Venous Return to the Heart</b></p> <ul style="list-style-type: none"><li>Deoxygenated blood returns to the heart via th</li></ul>  |

712



Chapter Twenty-Three Vessels and Circulation

## Challenge Yourself

Actively write or type your answers in a separate document to reinforce your learning, before checking your answers.

### Multiple Choice

Select the best answer from the four choices provided.

- Which vessel type consists of a tunica intima with large gaps between the endothelial cells, and a discontinuous basement membrane?
  - continuous
  - arteriole
  - sinusoid
  - fenestrated
- Some venous blood from the lower limb drains through which of the following veins?
  - great saphenous vein
  - basilic vein
  - external jugular vein
  - median cubital vein
- Which of the following vessels supplies the stomach wall and is not a direct branch of the celiac trunk?
  - splenic artery
  - right gastric artery
  - left gastric artery
  - common hepatic artery
- Which type of vessel has a large number of smooth muscle cell layers in its tunica media as well as elastic tissue confined to an internal elastic lamina and external elastic lamina?
  - elastic artery
  - muscular artery
  - arteriole
  - venule
- Which statement is true about veins?
  - Veins always transport deoxygenated blood.
  - Veins drain into smaller vessels called venules.
  - The largest tunic in a vein is the tunica externa.
  - The lumen of a vein tends to be smaller than that of a comparably sized artery.
- Which of the following is the pathway that blood follows through the upper limb arteries?
  - subclavian → axillary → ulnar → radial → brachial
  - subclavian → axillary → brachial → cephalic → basilic
  - subclavian → ulnar → brachial → radial
  - subclavian → axillary → brachial → radial and ulnar
- Which of the following veins typically does *not* drain directly into the inferior vena cava?
  - renal
  - hepatic portal
  - common iliac
  - right gonadal
- After birth, the umbilical vein becomes which structure?
  - medial umbilical ligament
  - ligamentum venosum
  - ligamentum arteriosum
  - round ligament of the liver

- The left fourth aortic arch vessel in an embryo becomes which structure?
  - left common carotid artery
  - left subclavian artery
  - aortic arch
  - left pulmonary artery
- Vasa vasorum are found in which tunic of a large blood vessel?
  - intima
  - media
  - externa
  - intermedia

### Content Review

- What are the respiratory and skeletal muscular pumps, and how do they assist in the return of venous blood to the heart?
- Compare and contrast arteries and veins with respect to function, tunic size, and lumen size.
- Trace the path of blood flow from the left ventricle of the heart to the right atrium of the heart. List the types of vessels (e.g., elastic arteries, arterioles) the blood travels through, and identify the type of blood vessel in which gas and nutrient exchange occur.
- What is the main function of capillaries? What are the three kinds of capillaries?
- Is blood pressure higher in arteries or veins? What are the consequences of hypertension?
- Identify the three main branches of the aortic arch that receive oxygenated blood, and identify the areas of the body they supply.
- How is blood flow through the upper and lower limbs similar?
- Compare the systemic and pulmonary circulations. Discuss the function of arteries and veins in each system.
- How does aging affect blood vessel anatomy and function?
- What postnatal changes occur in the heart and blood vessels? Why do these occur?

### Developing Critical Reasoning

- Two 50-year-old men are trying to determine their risk for developing atherosclerosis. John jogs three times a week, maintains a healthy weight, and eats a diet low in saturated fats. Thomas rarely exercises, is overweight, and only occasionally eats healthy meals. Based on your knowledge of the cardiovascular system and atherosclerosis, which man do you think is more at risk for developing the disease? What other factors could put a person at risk for atherosclerosis?
- Arteries tend to have a lot of vascular anastomoses around body joints (such as the elbow and knee). Propose a reason why this would be beneficial.

## Answers to "What Do You Think?"

- A smoker would have elevated blood pressure, because nicotine increases cardiac output and causes vasoconstriction.
- Blood could still reach the brain through the vertebral arteries. However, it is unlikely that these arteries could provide sufficient blood to the entire brain and head.
- If the left ulnar artery were cut, the left hand and fingers could still receive blood via the left radial artery.
- If the right femoral artery were blocked, blood flow to the right leg would be cut off; in other words, the popliteal artery and the branches to the leg would not receive any blood.

A carefully devised set of learning aids at the end of each chapter helps students review the chapter content, evaluate their grasp of key concepts, and utilize what they have learned. Reading the chapter summary and completing the Challenge Yourself exercises is a great way to assess learning.

## Chapter Summary Tables

Chapter summaries are presented in a concise, bulleted table format that provides a basic overview of each chapter. Section and page references make it easy to look up topics for review.

## Challenge Yourself

This battery of matching, multiple-choice, short answer, and critical-thinking questions is designed to test students on all levels of learning, from basic comprehension to synthesis of concepts.

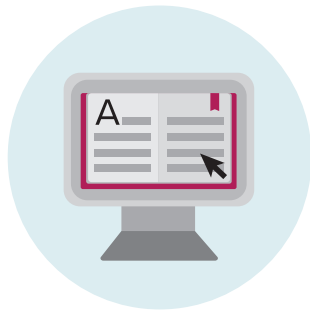## Answers to What Do You Think?

The What Do You Think? questions are answered at the end of each chapter.

**McGraw-Hill Connect® empowers students to learn and succeed in the Anatomy and Physiology course with user-friendly digital solutions.**

**SMARTBOOK®**

**SmartBook 2.0** provides personalized learning to individual student needs, continually adapting to pinpoint knowledge gaps and focus learning on concepts requiring additional study. **The result? Students are highly engaged in the content and better prepared for lecture.**



**LEARNSMART PREP®**

**LearnSmart Prep** helps students thrive in college-level A&P by helping solidify knowledge in the key areas of cell biology, chemistry, study skills, and math. **The result? Students are better prepared for the A&P course.**

**PracticeATLAS**




**Practice Atlas for A&P** is an interactive tool that pairs images of common anatomical models with stunning cadaver photography, allowing students to practice naming structures on both models and human bodies, anytime, anywhere. **The result? Students are better prepared, engaged, and move beyond basic memorization.**



**Ph.I.L.S.**

**Ph.I.L.S. 4.0 (Physiology Interactive Lab Simulations)** software is the perfect way to reinforce key physiology concepts with powerful lab experiments. **The result? Students gain critical thinking skills and are better prepared for lab.**



**Concept Overview Interactives** are groundbreaking interactive animations that encourage students to explore key physiological processes and difficult concepts. **The result? Students are engaged and able to apply what they've learned while tackling difficult A&P concepts.**

**Anatomy & Physiology Revealed® 4.0**



**Anatomy & Physiology Revealed® (APR) 4.0** is an interactive cadaver dissection tool to enhance lecture and lab that students can use anytime, anywhere. **The result? Students are prepared for lab, engaged in the material, and utilize critical thinking.**

**Stop the Drop!**  
50% of the country's students are unable to pass the A&P course\*

\*Statistic courtesy of *The New England Journal of Higher Education*





# connect<sup>®</sup>

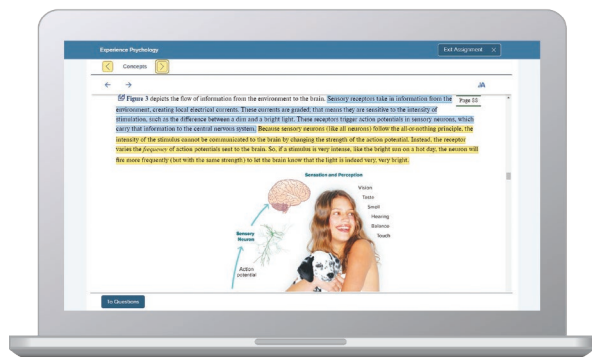
## FOR INSTRUCTORS

### You're in the driver's seat.

Want to build your own course? No problem. Prefer to use our turnkey, prebuilt course? Easy. Want to make changes throughout the semester? Sure. And you'll save time with Connect's auto-grading too.

# 65%

Less Time Grading



Laptop: McGraw-Hill; Woman/dog: George Doyle/Getty Images

### They'll thank you for it.

Adaptive study resources like SmartBook<sup>®</sup> 2.0 help your students be better prepared in less time. You can transform your class time from dull definitions to dynamic debates. Find out more about the powerful personalized learning experience available in SmartBook 2.0 at [www.mheducation.com/highered/connect/smartbook](http://www.mheducation.com/highered/connect/smartbook)

### Make it simple, make it affordable.



Connect makes it easy with seamless integration using any of the major Learning Management Systems—Blackboard<sup>®</sup>, Canvas, and D2L, among others—to let you organize your course in one convenient location. Give your students access to digital materials at a discount with our inclusive access program. Ask your McGraw-Hill representative for more information.

Padlock: Jobalou/Getty Images

### Solutions for your challenges.



A product isn't a solution. Real solutions are affordable, reliable, and come with training and ongoing support when you need it and how you want it. Our Customer Experience Group can also help you troubleshoot tech problems—although Connect's 99% uptime means you might not need to call them. See for yourself at **status.mheducation.com**

Checkmark: Jobalou/Getty Images

**SUPPORT** AT  
*every step*

## FOR STUDENTS

### Effective, efficient studying.

Connect helps you be more productive with your study time and get better grades using tools like SmartBook 2.0, which highlights key concepts and creates a personalized study plan. Connect sets you up for success, so you walk into class with confidence and walk out with better grades.

### Study anytime, anywhere.

Download the free ReadAnywhere app and access your online eBook or SmartBook 2.0 assignments when it's convenient, even if you're offline. And since the app automatically syncs with your eBook and SmartBook 2.0 assignments in Connect, all of your work is available every time you open it. Find out more at [www.mheducation.com/readanywhere](http://www.mheducation.com/readanywhere)

*"I really liked this app—it made it easy to study when you don't have your textbook in front of you."*

- Jordan Cunningham,  
Eastern Washington University



Calendar: owattaphotos/Getty Images

### No surprises.

The Connect Calendar and Reports tools keep you on track with the work you need to get done and your assignment scores. Life gets busy; Connect tools help you keep learning through it all.

### Learning for everyone.

McGraw-Hill works directly with Accessibility Services Departments and faculty to meet the learning needs of all students. Please contact your Accessibility Services office and ask them to email [accessibility@mheducation.com](mailto:accessibility@mheducation.com), or visit [www.mheducation.com/about/accessibility](http://www.mheducation.com/about/accessibility) for more information.

Top: Jenner Images/Getty Images, Left: Hero Images/Getty Images, Right: Hero Images/Getty Images



# Laboratory Resources

## Eckel's Human Anatomy Laboratory Manual, 3<sup>rd</sup> Edition

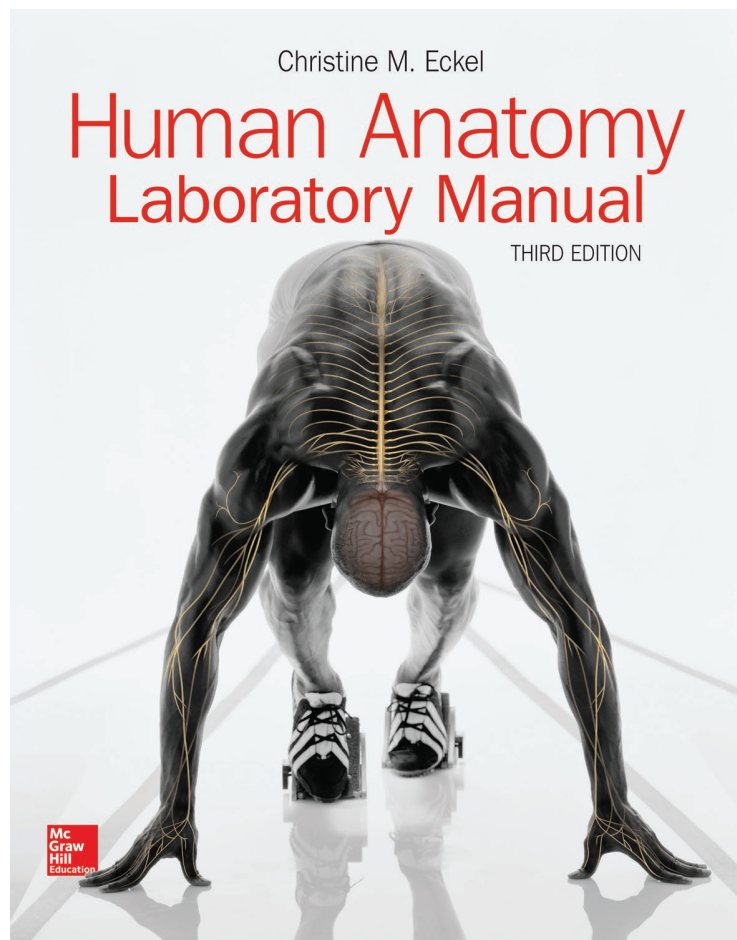
The *Human Anatomy Laboratory Manual*, by Christine Eckel of University of Indiana, is expressly written to supplement and expand upon content covered in the lecture course—not to repeat it. This highly customizable, hands-on learning tool guides students through human anatomy lab exercises using observation, touch, dissection, and practical activities such as sketching, labeling, and coloring. The manual focuses on human specimens and also includes common animal dissections such as cow bone, cow eye, sheep brain, and sheep heart.

Supplemental resources include Connect<sup>®</sup>, assignable and auto-gradable Pre- and Post-Lab questions, LearnSmart Prep, Anatomy & Physiology REVEALED 4.0, and a full eBook.

## Broyles' Workbook to Accompany Anatomy & Physiology REVEALED

The *Workbook to Accompany Anatomy and Physiology Revealed 4.0*, third edition, by Robert Broyles, is a workbook/study guide designed to help students get the most they can out of Anatomy and Physiology REVEALED 4.0 (APR), and out of their anatomy and physiology course. The Table of Contents closely follows APR and is organized along the lines of a typical Anatomy and Physiology course. The individual exercises include art from APR and also have review questions, tables, coloring exercises, terminology quiz questions, and reminders on key content.

*For additional details and customization opportunities, please contact your Learning Technology Representative.*



Mike Powell/The Image Bank/Getty Images

## ACKNOWLEDGMENTS

**M**any people worked with us to produce this text. Thanks go to our book team members at McGraw-Hill who attended to the many tasks involved in bringing this edition and its supporting materials to market: Matthew Garcia, Portfolio Manager; Donna Nemmers, Product Developer; Jessica Portz and Brent dela Cruz, Content Project Managers; David Hash, Designer; and Lori Hancock, Content Licensing Specialist. Over the span of six editions, we have been fortunate to work with the following individuals who contributed their specific talents to various tasks: Christine Eckel, cadaver dissection and photography; Jw Ramsey, surface anatomy photography; Al Telser, photomicroscopy; Mark Braun, clinical consultant; and Frank Baker, language consultant.

Reviewers have evaluated the fifth edition and provided invaluable comments and suggestions to help us continually improve this

textbook. We thank the fifth edition reviewers for their recommendations, which have helped us to improve this sixth edition.

Also, in this edition, we are very pleased to have been able to incorporate real student data points and input, derived from thousands of our LearnSmart users, to help guide our revision. LearnSmart Heat Maps provided a quick visual snapshot of usage of portions of the text and the relative difficulty students experienced in mastering the content. With these data, we were able to hone not only our text content but also the LearnSmart probes.

Finally, we could not have performed this effort were it not for the love and support of our families. They provided us with the encouragement we needed, were forgiving when our book schedules made it seem as if we were working all the time, and made sacrifices along with us in order to see this project to fruition.

### Reviewers

Stephanie Bender  
*Grand Valley State University*

Sandi Brown  
*Johnson County Community College*

Diep Burbridge  
*Long Beach City College*

William E. Cullinan  
*Marquette University*

Barbara E. Davis  
*Eastern Kentucky University*

Danielle Dodenhoff  
*California State University—Bakersfield*

John Fitzsimmons  
*Michigan State University*

Allan Forsman  
*East Tennessee State University*

Eric Green  
*Salt Lake Community College*

Karri Haen Whitmer  
*Iowa State University*

Lyon H. Hough  
*Missouri State University*

Elizabeth O. Lobo  
*Cuesta College*

Tyler Morris  
*Missouri State University*

Natalie Reynolds  
*Carl Albert State College*

### Clinical Views

#### Chapter 1 | A First Look at Anatomy

- 1.1 Clinicians' Use of Scientific Method
- 1.2 Etiology (Causes) and Pathogenesis (Development) of Disease
- 1.3 Medical Imaging Procedures

#### Chapter 2 | The Cell: Basic Unit of Structure and Function

- 2.1 Cystic Fibrosis and Chloride Channels
- 2.2 Tay-Sachs Disease
- 2.3 Adrenoleukodystrophy (ALD)
- 2.4 MELAS and Mitochondria
- 2.5 Characteristics of Cancer Cells

#### Chapter 3 | Embryology

- 3.1 Nondisjunction
- 3.2 Chromosomal Abnormalities and Spontaneous Abortion (Miscarriage)
- 3.3 Twinning
- 3.4 Infertility and Infertility Treatments
- 3.5 Congenital Malformations
- 3.6 Amniocentesis and Chorionic Villus Sampling
- 3.7 Preterm (Premature) Birth

#### Chapter 4 | Tissue Level of Organization

- 4.1 Stem Cells
- 4.2 What Are You Planning to Do with Your Baby's Umbilical Cord?
- 4.3 Systemic Lupus Erythematosus
- 4.4 Gangrene
- 4.5 Tissue Transplantation

#### Chapter 5 | Integumentary System

- 5.1 Tattoos
- 5.2 UV Radiation, Sunscreens, and Sunless Tanners
- 5.3 Nail Disorders
- 5.4 Acne and Acne Treatments
- 5.5 Burns
- 5.6 Treatments for Aging Skin
- 5.7 Psoriasis

#### Chapter 6 | Cartilage and Bone

- 6.1 Osteitis Deformans
- 6.2 Forensic Anthropology: Determining Age at Death
- 6.3 Achondroplastic Dwarfism
- 6.4 Rickets
- 6.5 Bone Scans
- 6.6 Osteoporosis

#### Chapter 7 | Axial Skeleton

- 7.1 Craniosynostosis and Plagiocephaly
- 7.2 Cleft Lip and Cleft Palate
- 7.3 Spinal Curvature Abnormalities
- 7.4 Herniated Discs
- 7.5 Sternal Foramen
- 7.6 Variations in Rib Development

#### Chapter 8 | Appendicular Skeleton

- 8.1 Fracture of the Clavicle
- 8.2 Colles Fracture
- 8.3 Scaphoid Fractures
- 8.4 Pott Fracture
- 8.5 Pathologies of the Foot
- 8.6 Limb Malformations

#### Chapter 9 | Articulations

- 9.1 Costochondritis
- 9.2 "Cracking Knuckles"
- 9.3 TMJ Disorders
- 9.4 Shoulder Joint Dislocations
- 9.5 Subluxation of the Head of the Radius
- 9.6 Fracture of the Femoral Neck
- 9.7 Knee Ligament and Cartilage Injuries
- 9.8 Ankle Sprains
- 9.9 Arthritis

#### Chapter 10 | Muscle Tissue and Organization

- 10.1 Tendonitis
- 10.2 Mitochondrial Myopathies

- 10.3 Muscular Paralysis and Neurotoxins
- 10.4 Rigor Mortis
- 10.5 Anabolic Steroids and Other Performance-Enhancing Compounds
- 10.6 Neuromuscular Diseases

#### **Chapter 11 | Axial Muscles**

- 11.1 Idiopathic Facial Nerve Paralysis (Bell Palsy)
- 11.2 Strabismus
- 11.3 Congenital Muscular Torticollis
- 11.4 Paralysis of the Diaphragm
- 11.5 Hernias
- 11.6 Evisceration

#### **Chapter 12 | Appendicular Muscles**

- 12.1 Paralysis of the Serratus Anterior Muscle (“Winged Scapula”)
- 12.2 Rotator Cuff Injuries
- 12.3 Lateral Epicondylitis (“Tennis Elbow”)
- 12.4 Carpal Tunnel Syndrome
- 12.5 Thigh Muscle Injuries
- 12.6 Plantar Fasciitis
- 12.7 Shin Splints and Compartment Syndrome

#### **Chapter 13 | Surface Anatomy**

- 13.1 Lip Color as a Diagnostic Tool
- 13.2 Surface Anatomy and CPR
- 13.3 Testing for Inguinal Hernias
- 13.4 Surface Anatomy and Lumbar Puncture
- 13.5 Gluteal Intramuscular Injections

#### **Chapter 14 | Nervous Tissue**

- 14.1 Neuroplasticity and Neurogenesis
- 14.2 Tumors of the Central Nervous System
- 14.3 Nervous System Disorders Affecting Myelin
- 14.4 Treating Spinal Cord Injuries
- 14.5 Amyotrophic Lateral Sclerosis
- 14.6 Neural Tube Defects

#### **Chapter 15 | Brain and Cranial Nerves**

- 15.1 Meningitis and Encephalitis
- 15.2 Epidural and Subdural Hematomas
- 15.3 Traumatic Brain Injuries: Concussion and Contusion
- 15.4 Hydrocephalus
- 15.5 Mapping Functional Brain Regions
- 15.6 Autism Spectrum Disorder
- 15.7 Effects of Alcohol and Drugs on the Cerebellum
- 15.8 Brain Disorders

#### **Chapter 16 | Spinal Cord and Spinal Nerves**

- 16.1 Lumbar Puncture and Epidural Injection
- 16.2 Shingles (Herpes Zoster)
- 16.3 Brachial Plexus Injuries
- 16.4 Sacral Plexus Nerve Injuries

#### **Chapter 17 | Pathways and Integrative Functions**

- 17.1 Cerebrovascular Accident
- 17.2 Epilepsy, Lobectomy, and Hemispherectomy
- 17.3 Dyslexia
- 17.4 Amnesia
- 17.5 Pathologic States of Unconsciousness
- 17.6 Alzheimer Disease: The “Long Goodbye”

#### **Chapter 18 | Autonomic Nervous System**

- 18.1 The Autonomic Nervous System and Cardiovascular Disease
- 18.2 Raynaud Syndrome
- 18.3 Horner Syndrome
- 18.4 Autonomic Dysreflexia

#### **Chapter 19 | Senses: General and Special**

- 19.1 Conjunctivitis
- 19.2 Detached Retina

- 19.3 Macular Degeneration
- 19.4 Cataracts
- 19.5 Glaucoma
- 19.6 How Vision Can Be Functionally Impaired
- 19.7 Otitis Media and Otitis Externa
- 19.8 Motion Sickness
- 19.9 Are Earbuds Bad for Your Health?
- 19.10 Cochlear Implants

#### **Chapter 20 | Endocrine System**

- 20.1 Disorders of Growth Hormone Secretion
- 20.2 Hypophysectomy
- 20.3 Disorders of Thyroid Hormone Secretion
- 20.4 Disorders of Parathyroid Gland Secretion
- 20.5 Disorders of Adrenal Cortex Hormone Secretion
- 20.6 Conditions Resulting in Abnormal Blood Glucose Levels
- 20.7 Thyroid Gland Developmental Anomalies

#### **Chapter 21 | Blood**

- 21.1 Blood Doping
- 21.2 Anemia
- 21.3 Rh Incompatibility and Pregnancy
- 21.4 Whole Blood Versus Plasma Donations: What’s the Difference?
- 21.5 Leukemia

#### **Chapter 22 | Heart**

- 22.1 Pericarditis
- 22.2 Heart Sounds and Heart Murmurs
- 22.3 Teenage Athletes and Sudden Cardiac Death
- 22.4 Angina Pectoris and Myocardial Infarction
- 22.5 The Electrocardiogram
- 22.6 Cardiac Arrhythmia

#### **Chapter 23 | Vessels and Circulation**

- 23.1 Varicose Veins
- 23.2 Deep Vein Thrombosis
- 23.3 Hypertension and Hypotension
- 23.4 Detecting a Pulse Point
- 23.5 Atherosclerosis
- 23.6 Aneurysms
- 23.7 Patent Ductus Arteriosus

#### **Chapter 24 | Lymphatic System**

- 24.1 Lymphedema
- 24.2 HIV and AIDS
- 24.3 Tonsillitis and Tonsillectomy
- 24.4 Palpation of Lymph Nodes as Diagnostic Tool
- 24.5 Lymphoma

#### **Chapter 25 | Respiratory System**

- 25.1 Cystic Fibrosis
- 25.2 Laryngitis
- 25.3 Aspiration of Foreign Bodies and the Heimlich Maneuver
- 25.4 Tracheotomy and Cricothyrotomy
- 25.5 Pneumothorax
- 25.6 Pneumonia
- 25.7 Asthma
- 25.8 Smoking, Emphysema, and Lung Cancer
- 25.9 Sudden Infant Death Syndrome (SIDS)

#### **Chapter 26 | Digestive System**

- 26.1 Reflux Esophagitis and Gastroesophageal Reflux Disease
- 26.2 Peptic Ulcers
- 26.3 Appendicitis
- 26.4 Diverticulosis and Diverticulitis
- 26.5 Colorectal Cancer
- 26.6 Cirrhosis of the Liver
- 26.7 Gallstones (Cholelithiasis)
- 26.8 Intestinal Disorders

**Chapter 27 | Urinary System**

- 27.1 Intravenous Pyelogram
- 27.2 Renal Failure, Dialysis, and Kidney Transplants
- 27.3 Renal Calculi
- 27.4 Urinary Tract Infections
- 27.5 Kidney Variations and Anomalies

**Chapter 28 | Reproductive System**

- 28.1 Ovarian Cancer
- 28.2 Cervical Cancer

- 28.3 Endometriosis
- 28.4 Contraception Methods
- 28.5 Breast Cancer
- 28.6 Benign Prostatic Hyperplasia and Prostate Cancer
- 28.7 Circumcision
- 28.8 Sexually Transmitted Infections
- 28.9 Intersex Conditions (Disorders of Sex Development)